

Case Report: *Baylisascaris procyonis* and Herpes Simplex Virus 2 Coinfection Presenting as Ocular Larva Migrans with Granuloma Formation in a Child

Grace Liu, Glenn Fennelly, Kevin R. Kazacos, Charles Grose, Joanna Dobroszycki, Norman Saffra, Christina M. Coyle, Louis M. Weiss, Moshe M. Szlechter, and Herbert B. Tanowitz*

Department of Ophthalmology and Visual Sciences, Albert Einstein College of Medicine, Bronx, New York; Department of Pediatrics, Albert Einstein College of Medicine, New York City, New York; Department of Pathology, Albert Einstein College of Medicine, Bronx, New York; Department of Medicine, Albert Einstein College of Medicine, and Jacobi Medical Center, Bronx, New York; Department of Comparative Pathobiology, Purdue University College of Veterinary Medicine, West Lafayette, Indiana; Virology Laboratory, University of Iowa Children's Hospital, Iowa City, Iowa

Abstract. Ocular *Baylisascaris procyonis* infection results from ingestion of infective eggs of *B. procyonis*, the raccoon ascarid. Herpes simplex virus type 2 (HSV-2) infection of the retina is the result of either primary infection or reactivated disease. Herein, we report a case of a 12-year-old female resident of the Bronx in New York City, who presented with pan-uveitis and vision loss. Initial evaluation for etiologic causes was nondiagnostic. Serology for anti-*Baylisascaris procyonis* antibodies in serum and vitreous fluid were both positive. Polymerase chain reaction (PCR) of vitreous fluid was positive for HSV-2. Treatment with vitrectomy, albendazole, and acyclovir resulted in mild improvement of visual acuity. The atypical presentation of *B. procyonis* in this case, as ocular larva migrans with a peripheral granuloma and retinal detachment, underscores the importance of maintaining a high degree of suspicion for this pathogen even in non-diffuse unilateral subacute neuroretinitis (DUSN) patients in urban areas. This case further illustrates that it is possible to have coexisting infections in cases of posterior uveitis.

Baylisascaris procyonis is a large ascarid that commonly parasitizes raccoons in North America and Europe.¹ It is a common cause of clinical larva migrans in animals and also affects humans, causing either neural larva migrans (NLM) affecting the nervous system and/or ocular larva migrans (OLM) and diffuse unilateral subacute neuroretinitis (DUSN) causing visual impairment.^{1–3} Animals and humans become infected by ingesting infective eggs from areas or articles contaminated with raccoon feces.¹ We diagnosed a young girl with *Baylisascaris* OLM, from the Borough of the Bronx in New York City. This patient is of particular interest because she had an atypical presentation for *Baylisascaris* OLM and was positive for anti-*B. procyonis* antibodies in her vitreous fluid as well as being seropositive in serum. In addition, polymerase chain reaction (PCR) testing of the vitreous fluid was positive for Herpes simplex virus-2 (HSV-2) DNA. The patient had mild improvement in visual acuity after diagnostic and therapeutic vitrectomy and treatment with albendazole and acyclovir.

CASE REPORT

The patient was a 12-year-old female born and raised in the Bronx, New York City, in an area bordering the suburban County of Westchester. She presented to the emergency department of the Jacobi Medical Center, Bronx, New York City, complaining of “redness and pain” in and about her right eye after reportedly being “poked” in that eye 5 days before. Her medical history included perinatal exposure to human immunodeficiency virus (HIV), bronchiolitis, attention deficit hyperactivity disorder, and she wore corrective glasses for astigmatism from age 2 to 7 years. There was a puppy in the household and she reported having played with several stray cats and had seen raccoons in the neighbor-

hood. There was no history of pica and the remainder of the review of systems was negative.

Initially, her best corrected visual acuity was finger counting at two feet in the right eye and 20/200 in the left eye at distance. There was no afferent papillary defect. The right eyelid showed mild periorbital edema, with 2+ injection of her conjunctiva. Anterior segment exam revealed endothelial keratic precipitates and 3+ cells without flare in the anterior chamber. Intraocular pressures were 10 and 12 in the right and left eyes, respectively. On dilated funduscopic examination, a hazy view with approximately 3+ vitritis prevented visualization of the right fundus. Ultrasound confirmed a dense vitritis. The left eye posterior segment had a quiescent chorioretinal scar inferotemporally, approximately 1.5 disc diameters in size, without any overlying vitritis. The anterior segment of the left eye was normal. No nematode larvae were visualized in the eyes.

The patient was initially treated for presumed ocular toxoplasmosis with trimethoprim-sulfamethoxazole and prednisone. In addition, she was given a topical regimen of prednisolone acetate 1% and cyclogyl 1%. Serum serology was done for *Toxocara*, *Toxoplasma*, HSV, and syphilis, and later for *Baylisascaris*. Angiotensin-converting enzyme, human leukocyte antigen B-27, and rheumatoid factor were negative. C-reactive protein and the erythrocyte sedimentation rate were within normal limits and eosinophilia was absent. The chest X-ray and tuberculin skin test were negative.

On multiple subsequent visits, her anterior segment exam improved, but the dense vitritis persisted, and her vision just before surgery was hand motion in the right eye. On a subsequent exam, a membrane extending from the posterior pole near the optic nerve to the periphery was noted (Figure 1), raising the suspicion for *Toxocara* OLM despite the negative serology. She was treated for *Toxocara* with albendazole 200 mg twice daily, the trimethoprim-sulfamethoxazole was discontinued and the topical regimen was continued. Subsequent serum serology for *Baylisascaris* was positive (optical density [OD] = 0.476; positive > 0.250; serum dilution 1:200). Because of her non-clearing vitritis and suspicious-appearing retinal

*Address correspondence to Herbert B. Tanowitz, Department of Pathology, Albert Einstein College of Medicine, 1300 Morris Park Avenue, Bronx, NY 10461. E-mail: herbert.tanowitz@einstein.yu.edu

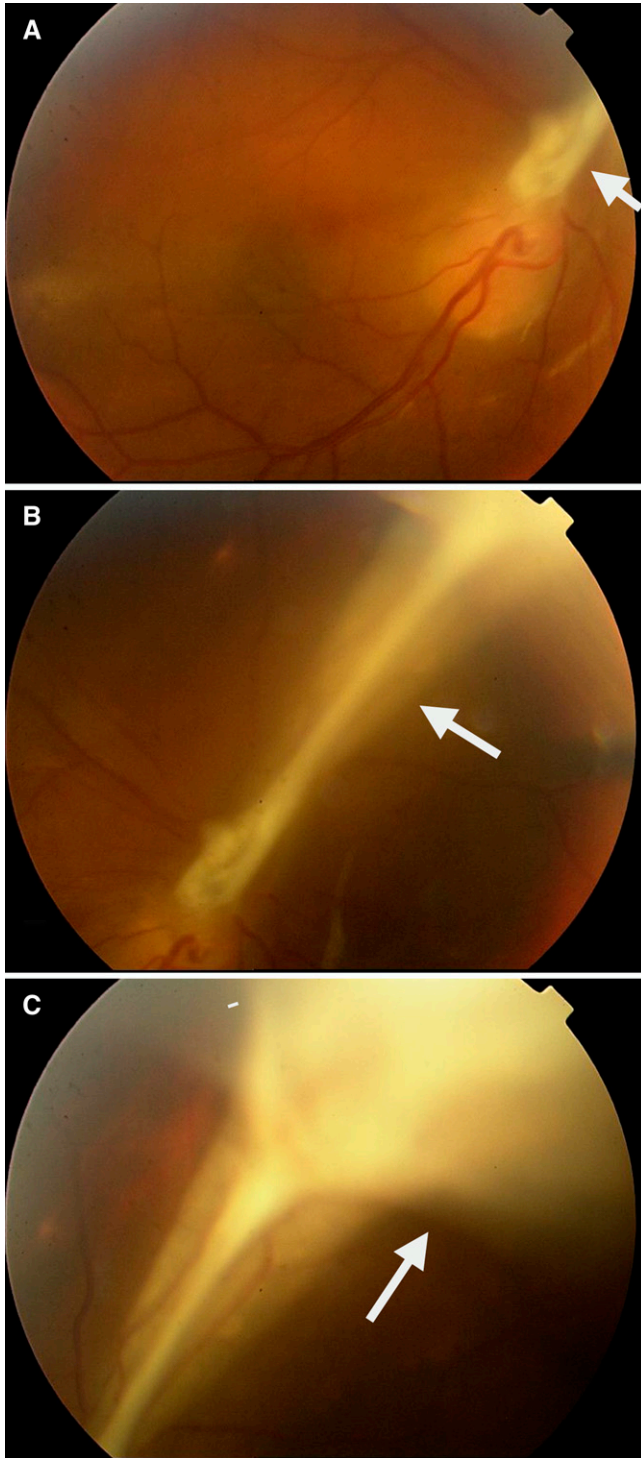


FIGURE 1. Photo of the fundus of the right eye: (A) note the peripheral granuloma (arrow) extending from optic nerve to periphery (see B). (B) Peripheral view of the right eye (note the optic nerve at the lower left corner) showing a posterior pole granuloma. (C) A view of the far periphery of the right eye showing proximal extent of the posterior pole granuloma causing a tractional retinal detachment.

membrane, she had a pars plana vitrectomy with membrane dissection of the right eye. Undiluted vitreous fluid was obtained by aspiration and submitted for PCR for HSV, and for herpes zoster virus (HZV) Cytomegalovirus and *Toxoplasma*,

serology for *Toxocara* and *Baylisascaris*, and for routine cytology and culture. After adequate core vitrectomy, visualization of the fundus revealed extensive membrane formation above a large retinal fold extending nasal from a granuloma at the posterior pole (Figure 1). Careful minimal dissection of the membranes was performed. Also noted was a mild amount of subretinal fluid in the peripapillary region. Vitreous fluid was PCR-positive for HSV-2 DNA as well as being seropositive for *Baylisascaris* (OD = 0.286; positive > 0.250; fluid dilution 1:10). There was no histopathology performed and the cytology of the vitreous fluid revealed benign squamous cell and lymphocytes. Serum serology detected both HSV-1- and HSV-2-specific antibodies. Albendazole, acyclovir, and corticosteroids were given by mouth. Acyclovir was administered for 1 year. The patient's visual acuity remained at counting fingers.

DISCUSSION

This case represents the first confirmed case of baylisascariasis presenting as classic end-stage OLM with granuloma formation rather than the more commonly associated lesions of DUSN. Despite the fact that a larva could not be visualized in the eye, of particular interest was the observation of a positive *Baylisascaris* serology in the vitreous fluid, in addition to being seropositive in the serum. This has not been reported previously in cases of *Baylisascaris* OLM–DUSN, but is well-known for *Toxocara* infections. Often in cases of toxocaral OLM, and also presumably with *Baylisascaris* OLM, patients may be seronegative in serum but positive for antibodies in ocular fluid. This is related to low-level infection, with chance migration of a larva into the eye, where it incites a localized response.^{1–3} This underscores the fact that in OLM cases it is more diagnostic to perform serology on both fluids. Ocular antibodies in toxocaral OLM are often much higher than the serum titer, and may be detected even though the serum is negative⁴; this would also apply to some cases of *Baylisascaris* OLM, but in our patient both compartments were seropositive. Examination of the right eye revealed peripheral posterior pole granuloma with a membrane extending from the optic nerve to the periphery, as well as a tractional retinal detachment. Retinal detachment has not been reported previously in *Baylisascaris* infection but is well-known to occur in some *Toxocara* infections with granuloma formation. Retinal necrosis rather than retinal detachment is typically observed in HSV-2 infections⁵; however, this child did not have retinal necrosis clinically.

Baylisascaris procyonis is the most common cause of the “large nematode variant” of DUSN,^{1–3} a type of OLM with progressive visual loss secondary to inflammation of the retina, retinal vessels, and optic nerve.^{6,7} DUSN is manifested by the early loss of central vision, inflammation of the vitreous fluid, and edema of the optic disc. In addition, there are recurrent crops of gray–white lesions that affect the outer retina and pigment epithelium.^{6,7} These are considered to be inflammatory migration tracks associated with migrating larvae,⁸ and were also seen in experimentally infected primates.^{9,10} There is also inflammatory sheathing of retinal vessels. Eventually, there is optic atrophy, narrowing of retinal vessels, hypopigmentation, and visual field loss.^{6,7} These findings appear to be the result of eosinophilic inflammation stimulated by migrating larvae, with subsequent infiltration and degranulation of eosinophils resulting in ocular tissue damage.^{8,9}

Migrating larvae release highly antigenic excretory–secretory products including enzymes and wastes that trigger the eosinophilic inflammatory reaction.^{4,8} There may be a sudden decrease in vision in one eye. Larvae that are observed in the retina are much larger than those of *Toxocara*, and are best treated by laser photocoagulation.^{2,3,11} The infection is also treated using steroids to reduce inflammation and albendazole to kill the parasites. The visual loss encountered with this infection is variable and in most cases treatment has not resulted in any significant improvement. In cases of heavier infection, *B. procyonis* typically produces meningoencephalitis, which is often irreversible, and may include concomitant ocular involvement with DUSN.^{2,3}

All reported cases of *Baylisascaris* OLM in humans to date have had lesions of DUSN associated with active migration of intraocular larvae. Although granuloma formation and associated retinal detachment would be expected in *B. procyonis* OLM (as seen in OLM due to *Toxocara* species), before this case it has not been reported. However, intraocular granulomas were noted in nonhuman primates and rodents experimentally infected with *B. procyonis*, along with lesions of DUSN.^{9,10}

There is a plausible explanation for the coexisting HSV-2 infection in the right eye. This girl was born to an HIV-infected mother and most likely acquired an asymptomatic neonatal HSV-2 infection, which at age 12 was reactivated in the eye. Eight similar published cases exist of HSV-2 reactivation in the eye in children and young adults with asymptomatic perinatal HSV-2 infections.⁵ All eight cases had retinal necrosis, a clinical diagnosis for which a biopsy is routinely performed. In the absence of clinical findings of retinal necrosis in this case, neither retinal biopsy nor HSV testing was immediately performed. It is believed that the *Baylisascaris* infection was responsible for the chronic damage to the eye of this patient, and that she acquired the infection in the urban environment of New York City, similar to what occurred in two other cases.^{11,12} Raccoon sightings are common in the part of New York City where the patient resides and raccoons in the northeastern United States are commonly infected with *B. procyonis*.¹

This case demonstrates that patients with infectious uveitis may harbor more than one infectious agent, so comprehensive evaluations are essential even in the setting of classic presentations. This case further illustrates that even in an urban setting, *Baylisascaris* OLM infections should be considered in the differential diagnosis, and that patients can have an atypical presentation with other ocular lesions present besides those of DUSN.

Received April 8, 2015. Accepted for publication May 20, 2015.

Published online June 29, 2015.

Financial support: This work was supported in part by NIH Grant AI-89716 (CG).

Authors' addresses: Grace Liu, Pediatric Ophthalmic Consultants, New York, NY, and the Department of Ophthalmology, New York University Langone School of Medicine, New York, NY, E-mail: mailgraceliu@gmail.com. Norman Saffra and Moshe M. Szlechter, Department of Ophthalmology and Visual Sciences, Albert Einstein College of Medicine, Bronx, NY, E-mails: eyesitemd@gmail.com and moshe.szlechter@nbhn.net. Joanna Dobroszycki, Department of Pediatrics, Albert Einstein College of Medicine, Bronx, NY, E-mail: joanna.dobroszycki@nbhn.net. Glenn Fennelly, Department of Pediatrics, Rutgers New Jersey Medical School, Newark, NJ, E-mail: fennelgl@njms.rutgers.edu. Kevin R. Kazacos, Department of Comparative Pathobiology, Purdue University, West Lafayette, IN, E-mail: kkazacos@purdue.edu. Charles Grose, University of Iowa Children's Hospital, Iowa City, IA, E-mail: charles-grose@uiowa.edu. Christina M. Coyle and Louis M. Weiss, Department of Medicine, Albert Einstein College of Medicine, Bronx, NY, E-mails: christina.coyle@einstein.yu.edu and louis.weiss@einstein.yu.edu. Herbert B. Tanowitz, Department of Pathology, Bronx, NY, E-mail: herbert.tanowitz@einstein.yu.edu.

REFERENCES

1. Kazacos KR, 2001. *Baylisascaris procyonis* and related species. Samuel WM, Pybus MJ, Kocan AA, eds. *Parasitic Diseases of Wild Mammals*, 2nd edition. Ames, IA: Iowa State University Press, 301–341.
2. Gavin PJ, Kazacos KR, Shulman ST, 2005. Baylisascariasis. *Clin Microbiol Rev* 18: 703–718.
3. Kazacos KR, Jelicks LR, Tanowitz HB, 2013. *Baylisascaris* larva migrans. Garcia HH, Tanowitz HB, Del Brutto OH, eds. *Neuroparasitology and Tropical Neurology: Handbook of Clinical Neurology*, Vol. 114. Waltham, United Kingdom: Elsevier, 251–262.
4. Glickman LT, Magnaval JF, 1993. Zoonotic roundworm infections. *Infect Dis Clin North Am* 7: 717–732.
5. Grose C, 2012. Acute retinal necrosis caused by *Herpes simplex virus* type 2 in children: reactivation of an undiagnosed latent neonatal herpes infection. *Semin Pediatr Neurol* 19: 115–118.
6. Gass JDM, Braunstein RA, 1983. Further observations concerning the diffuse unilateral subacute neuroretinitis syndrome. *Arch Ophthalmol* 101: 1689–1697.
7. Gass JDM, Gilbert WR Jr, Guerry RK, Scelfo R, 1978. Diffuse unilateral subacute neuroretinitis. *Ophthalmology* 85: 521–545.
8. Kazacos KR, 1996. *Baylisascaris procyonis* and other helminth larvae as causes of ocular larva migrans and DUSN. *Proc Int Soc Ophthalmic Pathol and Am Assoc Ophthalmic Pathol* 20.
9. Kazacos KR, Raymond LA, Kazacos EA, Vestre WA, 1985. The raccoon ascarid. A probable cause of human ocular larva migrans. *Ophthalmology* 92: 1735–1743.
10. Kazacos KR, Vestre WA, Kazacos EA, 1984. Raccoon ascarid larvae (*Baylisascaris procyonis*) as a cause of ocular larva migrans. *Invest Ophthalmol Vis Sci* 25: 1177–1183.
11. Saffra NA, Perlman JE, Desai RU, Kazacos KR, Coyle CM, Machado FS, Kedhar SR, Engelbert M, Tanowitz HB, 2010. *Baylisascaris procyonis* induced diffuse unilateral subacute neuroretinitis in New York City. *J Neuroparasitol* 1: 4.
12. Perlman JE, Kazacos KR, Imperato GH, Desai RU, Schulman SK, Edwards J, Pontrelli LR, Machado FS, Tanowitz HB, Saffra NA, 2010. *Baylisascaris procyonis* neural larva migrans in an infant in New York City. *J Neuroparasitol* 1: 5.