

## BALAMUTHIA MANDRILLARIS MENINGOENCEPHALITIS: THE FIRST CASE IN SOUTHEAST ASIA

POJ INTALAPAPORN, CHUSANA SUANKRATAY, SHANOP SHUANGSHOTI, KAMMANT PHANTUMCHINDA, SOMBOON KEELAWAT, AND HENRY WILDE

Section of Infectious Diseases and Section of Neurology, Department of Medicine, and Department of Pathology, Chulalongkorn University, Bangkok, Thailand; Queen Saovabha Memorial Institute, Bangkok, Thailand

**Abstract.** We present a case of 23-year-old man with acute meningoencephalitis, accompanied by inflammation of a nasal ulcer. He had been healthy until six months prior to admission to the hospital when he had a motorcycle accident. A star-shaped wound at his nose was incurred after falling into a swamp. A computed tomogram of the brain showed two nonenhancing hypodense lesions at the left caudate nucleus and the right parietal lobe, ependymitis and leptomeningeal enhancement. A skin biopsy showed chronic noncaseous granulomatous inflammation without demonstrated microorganisms. The patient did not respond to the empirical treatment with cloxacillin, ceftriaxone, and amphotericin B, and eventually died on the thirteenth day of hospitalization. At autopsy, hematoxylin and eosin-stained brain sections showed a chronic necrotizing inflammation with numerous amebic trophozoites and rare cysts. Definitive identification of *Balamuthia mandrillaris* was made by fluorescent immunohistochemical analysis. There were 10 *Naegleria fowleri* primary amebic meningoencephalitis, eight *Acanthamoeba* granulomatous amebic encephalitis, and three *Acanthamoeba* meningitis in Thailand. To our knowledge, this case is the first reported case of *B. mandrillaris* in Southeast Asia.

### INTRODUCTION

There are two genera of small, free-living, aerobic amebae, *Naegleria* and *Acanthamoeba*, which can cause central nervous system (CNS) infections in humans.<sup>1,2</sup> *Acanthamoeba* meningitis and *Naegleria* primary meningoencephalitis were first reported in 1965 and 1966 in southern Australia and Florida.<sup>3,4</sup> However, *Balamuthia mandrillaris*, previously known as leptomyxid ameba, has become recognized as another human CNS pathogen.<sup>5–9</sup> Two distinct clinical syndromes of CNS infections are described: primary amebic meningoencephalitis (PAM) and granulomatous amebic encephalitis (GAE). Primary amebic meningoencephalitis is an acute fulminant necrotizing meningoencephalitis. It is caused by *Naegleria fowleri* that can gain access to the CNS by direct invasion through the nasal mucosa and cribriform plate. It occurs mostly in healthy children and young adults. Granulomatous amebic encephalitis, a subacute-to-chronic disease, is caused by *Acanthamoeba* spp. or *B. mandrillaris* that spreads hematogenously from pulmonary or skin lesions into the CNS. In contrast to *Acanthamoeba* spp., which appear more commonly in the elderly and immunocompromised hosts, *B. mandrillaris* is capable of infecting both healthy and immunosuppressed patients. *Balamuthia mandrillaris* was previously regarded as an innocuous soil organism incapable of infecting mammals. To date, it has been implicated by retrospective analysis in several previously undiagnosed or misdiagnosed cases of encephalitis or GAE that had been attributed to *Acanthamoeba*. One hundred fifty-six human cases of GAE have been reported from 1956 through 1997 at the Centers for Disease Control and Prevention (Atlanta, GA) 63 of them caused by *B. mandrillaris*.<sup>7</sup> We present the first reported case of *B. mandrillaris* meningoencephalitis from Southeast Asia.

### CASE REPORT

A 23-year-old man was admitted to Chulalongkorn University Hospital with a severe headache for three days. He had been healthy until six months prior to admission when he had

a motorcycle accident and had fallen into a swamp. A star-shaped wound at his nose was incurred. The patient did not seek medical help after the accident, and the wound became a chronic ulcer. One month prior to admission (five months after the accident), he noted swelling and serum oozing from the previously dry nasal lesion. He consulted a physician at a local hospital where oral antibiotics were prescribed, but there was no improvement. Two weeks prior to admission, he developed fever, chills, and headache in both the periorbital and temporal areas. He came to the Plastic Surgery Department of Chulalongkorn University Hospital where the nasal lesion was diagnosed as an inflamed keloid. He was given oral dicloxacillin and an intrakeloid steroid injection. One week prior to admission (seven days after intrakeloid injection), he still had a persistent severe headache and marked inflammation of his nasal ulcer. He was then transferred to the Department of Medicine for further investigation. The patient was born at Chaiyapoom in northeastern Thailand, and moved to Bangkok to work in a paper factory seven years ago. Other than for a history of alcohol abuse, his medical history was unremarkable.

A physical examination showed a temperature of 37.7°C, a blood pressure of 130/80 mm of Hg, a pulse rate of 80/minute, and respiratory rate of 20/minute. The patient was lethargic and confused. There was marked swelling, erythema, and tenderness of the nasal ulcer with turbid serum oozing from it (Figure 1). His nasal mucosa was normal. There were bilateral papilledema and mild nuchal rigidity, but no focal neurologic signs. The remaining results of the physical examination were unremarkable. A complete blood count showed a hematocrit of 40.9%, a white blood cell count of 11,300 cells/mm<sup>3</sup> (with 82.1% polymorphonuclear cells, 9.8% lymphocytes, 6.8% monocytes, and 1.2% eosinophils), and a platelet count of 388,000 cells/mm<sup>3</sup>. Serologic results for human immunodeficiency virus were negative. A chest radiograph showed no abnormalities. Computed tomography (CT) of the brain showed two nonenhancing hypodense lesions at the left caudate nucleus and the right parietal lobe that caused pressure effects on the left frontal horn and on both occipital horns of the lateral ventricles, respectively. There was also an evidence

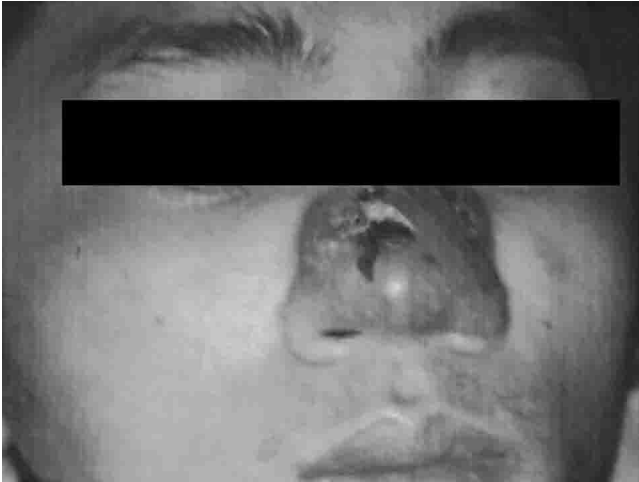

FIGURE 1. Nasal ulcer of the patient showing marked swelling, erythema, and tenderness.

of ependymitis of left frontal horn and diffuse leptomeningeal enhancement that was more prominent at the peripontine cistern. These findings were compatible with focal encephalitis or cerebritis with meningitis (Figure 2). A lumbar puncture yielded a clear colorless fluid with opening pressure of 30 cm of H<sub>2</sub>O, 262 mononuclear cells/mm<sup>3</sup>, a glucose level of 48 mg/dL (serum glucose level = 108 mg/dL), and a protein level of 100 mg/dL. No microorganisms were seen on Gram- and acid-fast bacilli (AFB)-stained smears or an India ink preparation. Tests results of the cerebrospinal fluid (CSF) for cryptococcal antigen and a polymerase chain reaction for *Mycobacterium tuberculosis* were negative. Gram-, AFB-, and Wright-stained smears of the discharge from the nasal ulcer were negative. The patient was treated empirically for bacterial cerebritis with intravenous cloxacillin (2 grams every 4 hours) and ceftriaxone (2 grams every 12 hours). On the fifth day of admission, he still had a severe headache accompanied

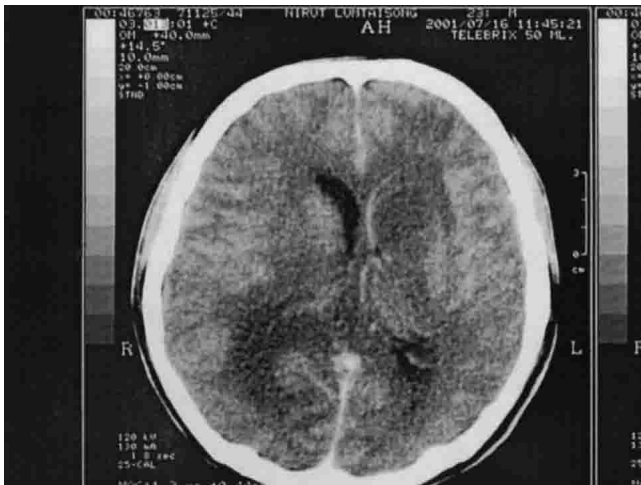

FIGURE 2. Computed tomography of the brain of the patient showing two nonenhancing lesions at the left caudate nucleus and the right parietal lobe that caused pressure effects on the left frontal horn and both occipital horns of the lateral ventricles, respectively. There was also evidence of ependymitis of the left frontal horn and diffuse leptomeningeal enhancement.

by nausea, vomiting, and high-grade fever, and a skin biopsy of the nasal ulcer was performed. Cultures of blood, wound discharges, and CSF were negative. Microscopic examination of the skin biopsy showed chronic, noncaseous, granulomatous inflammation of the dermis and subcutaneous tissue with a negative result for Gram, AFB, and Gomori-methenamine-silver (GMS) staining. On the seventh day of admission, his neurologic status deteriorated and there was no response to painful stimuli. An emergency CT of the brain showed persistent lesions with generalized cerebral edema and a midline shift of 0.9 cm to the left side. Intravenous amphotericin B was administered empirically, but the patient eventually died on the thirteenth day of hospitalization (six months after his motorcycle accident).

At autopsy, the most significant findings were confined to the CNS. The swollen brain weighed 1,340 grams. The coronal sections showed two pale, yellow, soft necrotic lesions at the left caudate nucleus (4 cm in diameter) and the right parietal lobe (3 cm in diameter). Hematoxylin and eosin-stained brain sections showed numerous amebic trophozoites and rare cysts in the necrotic foci (Figure 3). The organisms tended to aggregate around blood vessels, and some invaded through the vascular wall. Small necrotic areas were noted in the pons, infiltrated by the trophozoites. There were also increased mononuclear inflammatory cells in the subarachnoid space. The diagnosis of amebic meningoencephalitis was then made. The case was investigated further at the Department of Neuropathology and Ophthalmic Pathology of the United States Armed Forces Institute of Pathology (Washington, DC) to confirm the diagnosis of GAE. Definite identification of the species of ameba was made by fluorescent immunohistochemistry at the National Center of Infectious Diseases of the Centers for Disease Control and Prevention. The ameba was identified as *B. mandrillaris*.

## DISCUSSION

*Balamuthia mandrillaris* was first isolated from the brain of a mandrill baboon at the San Diego Wild Animal Park.<sup>5</sup> Several reported cases of *B. mandrillaris* had initially been diagnosed as being due to *Acanthamoeba*.<sup>10</sup> Following the development of an immunofluorescence assay using rabbit antiserum to washed trophozoites and cysts from cultures of *B. mandrillaris*, a number of human cases of *B. mandrillaris* meningoencephalitis were diagnosed retrospectively.<sup>10</sup> Almost 100 cases of *B. mandrillaris* infections have been described worldwide. A total of 21 patients with free-living ameba infections of the CNS have been reported from Thailand.<sup>11</sup> There were 10 cases of *N. fowleri* PAM, 8 of *Acanthamoeba* GAE, and 3 of *Acanthamoeba* meningitis. To date, no case of *B. mandrillaris* infections has been reported from Thailand. However, it is likely that there may have been cases of *B. mandrillaris* GAE among some Thai patients diagnosed as *Acanthamoeba* GAE and a retrospective study of archived tissue samples would be of interest.

The environmental niche of *B. mandrillaris* is not known.<sup>12</sup> It has not been isolated from nature like other free-living amebae. However, *B. mandrillaris* is believed to be widely distributed in fresh water, soil, and dust throughout the world. Invasion and penetration into the CNS by hematogenous spread from a primary focus of infection in the respiratory

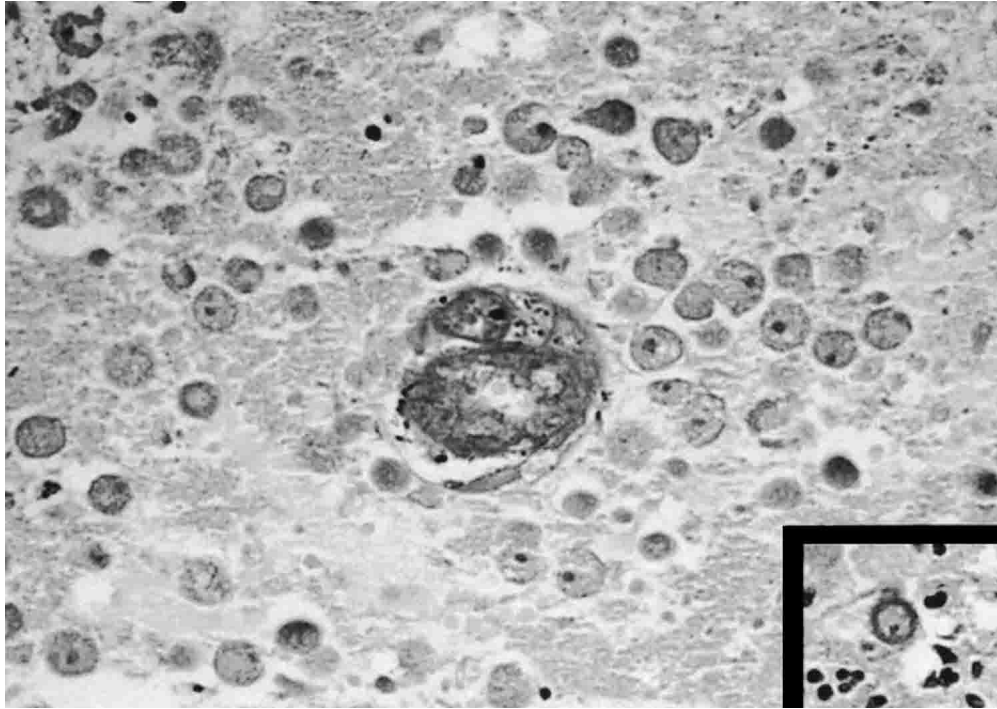


FIGURE 3. Brain sections of the patient showing an increased number of mononuclear inflammatory cells with amebic trophozoites and rare cysts in the necrotic foci. Note the perivascular arrangement of the organisms (magnification  $\times 400$ ). **Inset**, numerous trophozoites and a cyst of *Balamuthia mandrillaris* (magnification  $\times 100$ ). (Hematoxylin and eosin stained.)

tract or skin are the suggested portal of entry. Our patient was thrown into a swamp and the ameba could have entered through the skin injury. Prior cases of *B. mandrillaris* GAE presented with skin lesions of varying duration ranging from two months to three years.<sup>13,14</sup> Our patient had a chronically ulcerating skin lesion on his nose for six months prior to onset of his neurologic disease. A history of such skin lesions might be a useful clue for suspecting GAE in patients presenting with meningoencephalitis. However, one should note that *B. mandrillaris* also has been reported to involve the kidneys, adrenal glands, and lungs.<sup>5</sup>

The histopathology of *B. mandrillaris* infection is that of chronic inflammation composed of mostly lymphocytes, monocytes, plasma cells, and rare giant cells.<sup>7,15</sup> True granulomatous inflammation also has been described. *Balamuthia mandrillaris* trophozoites and cysts have been observed to be angiotropic, tending to cluster around blood vessels.<sup>7,15</sup> This may be responsible for hemorrhagic necrosis of the brain and meninges, as noted in our patient. On hematoxylin and eosin-stained preparations, *B. mandrillaris* is very difficult to distinguish from *Acanthamoeba*, but it is distinct from *Entamoeba histolytica*.<sup>10</sup> *Balamuthia mandrillaris* trophozoites, which range in size from 12 to 60  $\mu\text{m}$ , are uninucleated with a large, densely staining nucleolus. There may be two or three nucleoli in some trophozoites. In contrast, each *E. histolytica* trophozoite has a single small nucleolus with densely staining chromatin granules lining the nuclear membrane. *Balamuthia mandrillaris* cysts may be more readily visualized with either GMS or periodic acid-Schiff stains. They range in size from 6 to 30  $\mu\text{m}$  and appear to be double-walled and three-walled by light and electron microscopy, respectively. Immunofluorescence studies are required for differentiating between *B. mandrillaris* and *Acanthamoeba*.<sup>10</sup>

Most previous reports of *B. mandrillaris* infection were in healthy hosts, but some had associated human immunodeficiency virus infection, diabetes mellitus, or chronic renal failure.<sup>5</sup> There also were cases in intravenous drug users or chronic alcoholics as was noted in our patient. None of the pediatric patients were immunocompromised.<sup>5</sup>

Computed tomography or magnetic resonance imaging of the brain showed one or more lesions with or without enhancement, and may be accompanied by meningeal enhancement, as was noted in our patient. This appearance is non-specific and can be observed in bacterial, fungal, tuberculous, and *Toxoplasma* infections, or even neoplasm. Some reports suggest that in contrast to *Acanthamoeba* infection, which preferentially involves posterior structures of the brain such as the cerebellum, thalamus, or brainstem, *B. mandrillaris* infection may involve cortical areas more frequently.<sup>7,16</sup>

Although *B. mandrillaris* has not yet been identified in the CSF, a fresh wet-mount specimen should be examined for trophozoites in an effort to make an early diagnosis, as has been done with *N. fowleri*.<sup>7</sup> Recently, a cell-free growth medium has been developed to isolate *B. mandrillaris*.<sup>17,18</sup> Details of specimen processing and culture media have been reported by Schuster.<sup>18</sup> In addition, a murine model has been developed that can assess virulence and evaluate potential therapeutic strategies.<sup>19</sup>

Almost 100 human cases of *B. mandrillaris* GAE have now been reported worldwide. All died and no effective treatment has been found. However, several case reports suggested some response to pentamidine isethionate,<sup>17</sup> miconazole, 5-fluorocytosine,<sup>7</sup> and ketoconazole.<sup>7</sup> Fluconazole or amphotericin B was marginally effective. Azithromycin, clarithromycin, and trimethoprim-sulfamethoxazole have shown no effect. There is no information regarding efficacy of itracona-

zole and other new azoles. Lack of effective treatment and delay in the diagnosis of most reported cases may have contributed to the high mortality rate. Earlier diagnosis and treatment with the known marginally effective agents, as well as surgical excision of accessible brain lesions, may result in better clinical outcomes. Treatment of infection with *Acanthamoeba* and *N. fowleri* has been equally disappointing.<sup>1,2,4</sup>

In summary, we report the first case of *B. mandrillaris* meningoencephalitis from Southeast Asia. *Balamuthia mandrillaris* should be included in the differential diagnosis of normal and immunocompromised hosts presenting with subacute or chronic meningoencephalitis; especially if they have an associated skin lesion.

Received August 27, 2003. Accepted for publication October 30, 2003.

Acknowledgments: We are grateful to Dr. Elisabeth J. Rushing, the Assistant Chairperson, and Dr. Glenn D. Sandberg (Department of Neuropathology and Ophthalmic Pathology, United States Armed Forces Institute of Pathology, Washington DC) for kindly arranging to have the fluorescent immunohistochemical analysis performed at the National Center of Infectious Diseases, Centers for Disease Control and Prevention (Atlanta, GA).

Authors' addresses: Poj Intalaporn and Chusana Suankratay, Section of Infectious Diseases, Department of Medicine, Chulalongkorn University, Bangkok 10330, Thailand, Telephone: 66-2-256-4249, Fax: 66-2-256-4578, E-mail: schusana@hotmail.com. Shanop Shuangshoti and Somboon Keelawat, Department of Pathology, Chulalongkorn University, Bangkok 10330, Thailand. Kammant Phantumchinda, Section of Neurology, Department of Medicine, Chulalongkorn University, Bangkok 10330, Thailand. Henry Wilde, Queen Saovabha Memorial Institute, Bangkok 10330, Thailand.

## REFERENCES

1. Ma P, Visvesvara GS, Martinez AJ, Theodore FH, Daggett PM, Sawyer TK, 1990. *Naegleria* and *acanthamoeba* infections: review. *Rev Infect Dis* 12: 490–513.
2. Sison JP, Kemper CA, Loveless M, McShane D, Visvesvara GS, Deresinski SC, 1995. Disseminated *Acanthamoeba* infections in patients with AIDS: case reports and review. *Clin Infect Dis* 20: 1207–1216.
3. Fowler M, Carter RF, 1965. Acute pyogenic meningitis probably due to *Acanthamoeba* sp.: a preliminary report. *BMJ* 5464: 740–742.
4. Butt CG, 1966. Primary amebic meningoencephalitis. *N Engl J Med* 274: 1473–1476.
5. Visvesvara GS, Martinez AJ, Schuster FL, Leitch GJ, Wallace SV, Sawyer TK, Anderson M, 1990. Leptomyxid amoeba, a new agent of amebic meningo-encephalitis in humans and animals. *J Clin Microbiol* 28: 2750–2756.
6. Rowen JL, Doerr CA, Vogel H, Baker CJ, 1995. *Balamuthia mandrillaris*: a newly recognized agent for amebic meningoencephalitis. *Pediatr Infect Dis J* 14: 705–710.
7. Denney CF, Iragui VJ, Uber-Zak LD, Karpinski NC, Ziegler EJ, Visvesvara GS, Reed SL, 1997. Amebic meningoencephalitis caused by *Balamuthia mandrillaris*: case report and review. *Clin Infect Dis* 25: 1354–1358.
8. Gordon SM, Steinberg JP, DuPuis MH, Kozarsky PE, Nickerson JF, Visvesvara GS, 1992. Culture isolation of *Acanthamoeba* species and leptomyxid amebas from patients with amebic meningoencephalitis, including two patients with AIDS. *Clin Infect Dis* 15: 1024–1030.
9. Booton GC, Carmichael JR, Visvesvara GS, Byers TJ, Fuerst PA, 2003. Genotyping of *Balamuthia mandrillaris* based on nuclear 18S and mitochondrial 16S rRNA genes. *Am J Trop Med Hyg* 68: 65–69.
10. Martinez AJ, Visvesvara GS, 1991. Laboratory diagnosis of pathogenic free-living amoebas: *Naegleria*, *Acanthamoeba*, and *Leptomyxid*. *Clin Lab Med* 11: 861–877.
11. Sithinamsuwan P, Sangruchi T, Chiewvit P, Pongvarin N, 2001. Free-living amoeba infections of the central nervous system in Thailand. Report of two patients and review of the literature. *Intern Med J Thai* 17: 350–360.
12. Martinez AJ, Visvesvara GS, 2001. *Balamuthia mandrillaris* infection. *J Med Microbiol* 50: 205–207.
13. Recavarren-Arce S, Velarde C, Gotuzzo E, Cabrera J, 1999. Amoeba angeitic lesions of the central nervous system in *Balamuthia mandrillaris* amoebiasis. *Human Pathol* 30: 269–273.
14. Deol I, Robledo L, Meza A, Visvesvara GS, Andrew RJ, 2000. Encephalitis due to a free-living amoeba (*Balamuthia mandrillaris*): case report with literature review. *Surg Neurol* 53: 611–616.
15. Popek EJ, Neafie RC, 1992. Granulomatous meningoencephalitis due to leptomyxid amoeba. *Pediatr Pathol* 12: 871–881.
16. Katz JD, Ropper AH, Adelman L, Worthington M, Wade P, 2000. A case of *Balamuthia mandrillaris* meningoencephalitis. *Arch Neurol* 57: 1210–1212.
17. Schuster FL, Visvesvara GS, 1996. Axenic growth and drug sensitivity studies of *Balamuthia mandrillaris*, an agent of amebic meningoencephalitis in humans and other animals. *J Clin Microbiol* 34: 385–388.
18. Schuster FL, 2002. Cultivation of pathogenic and opportunistic free-living amoebas. *Clin Microbiol Rev* 15: 342–354.
19. Janitschke K, Martinez AJ, Visvesvara GS, Schuster FL, 1996. Animal model *Balamuthia mandrillaris* infection: contrast and comparison in immunodeficient and immunocompetent mice: a murine model of “granulomatous” amebic encephalitis. *J Neuropathol Exp Neurol* 55: 815–821.