

## INTRAOBSERVER AND INTEROBSERVER VARIATION OF ULTRASOUND DIAGNOSIS OF *OESOPHAGOSTOMUM BIFURCUM* COLON LESIONS

P. A. STOREY, N. SPANNBRUCKER, E. A. AGONGO, L. VAN LIESHOUT, J. P. ZEIM, P. MAGNUSSEN,  
A. M. POLDERMAN, AND E. DOEHRING

*Parasitology Department, Leiden University, Leiden, The Netherlands; Board of Public Health, Neuruppin, Germany; Upper East Regional Health Services, Bolgatanga, Ghana; School of Medicine and Health Sciences, University for Development Studies, Tamale, Ghana; Danish Bilharziasis Laboratory, Charlottenlund, Denmark*

**Abstract.** Infection by the nematode *Oesophagostomum bifurcum* is focally distributed in Africa and causes a syndrome of abdominal pain, obstruction, or abdominal mass because of its predilection for invasion of colonic mucosa. To determine the reliability of ultrasound for the detection of colon pathology induced by this parasite, three studies to assess the intraobserver and interobserver variation of the technique were performed. In an area of northern Ghana endemic for *O. bifurcum*, 181 people from a low-prevalence village and 62 people from a high-prevalence village were examined twice by the same observer, and 111 people were independently examined by two observers in a moderately endemic village. The  $\kappa$  statistics for the prevalence observations in the three studies were 0.82, 0.87, and 0.81, respectively, and  $\kappa$  values for the intensity observations were 0.66, 0.63, and 0.71, respectively. The upper 95% confidence intervals of the average absolute difference in nodule size measurements in Study 1 and Study 3 were 3.6 and 4.5 mm, respectively. Therefore, ultrasound is useful in the diagnosis and management of *O. bifurcum* colon infection.

### INTRODUCTION

*Oesophagostomum bifurcum*, an intestinal parasitic helminth, is highly and focally endemic in northern Ghana and Togo. An estimated 250,000 people are infected,<sup>1,2</sup> and village infection prevalence detected by stool culture varies from 0% to 79%. Juvenile worms develop within the colonic wall, causing inflammatory lesions. The lesions contain thick yellow pus and a white, living *Oesophagostomum* worm approximately 11 mm in length.<sup>3</sup> Patients can present with the so-called Dapaong tumor, a painful abdominal mass, 30–60 mm in diameter, which is frequently adherent to the abdominal wall. Peritonitis secondary to nodule rupture, bowel obstruction secondary to inflammatory adhesions, and the formation of cutaneous abscesses and fistulas can result.<sup>4–6</sup> Multinodular esophagostomiasis presents with diffuse abdominal pain, severe weight loss, and persistent diarrhea. Hundreds of pea-sized nodules can be found in a thickened edematous submucosa and subserosa of the large intestine.<sup>7–9</sup> Ultrasound visualizes a characteristic nodular target appearance in the colon.<sup>10</sup>

Preclinical colonic pathology can also be identified by ultrasound.<sup>11</sup> The characteristic nodular anechogenic lesions are a common finding in endemic villages and have been shown to contain juvenile *O. bifurcum* worms. Therefore, detection of colonic pathology before the development of symptoms is possible. However, estimation of the sensitivity and specificity of the ultrasound diagnosis of *O. bifurcum* pathology cannot be made because when the ultrasound appearance of the pathology was described,<sup>10</sup> surgical diagnosis and management were superseded by conservative chemotherapeutic treatment, followed by ultrasound to monitor colonic recovery.<sup>3</sup>

Sonography can be considerably handicapped by observer bias, regardless of formalized diagnostic criteria. Subjectivity is an inherent characteristic of ultrasound, not only in the real-time appraisal of the findings, but also in the decision as to which view to represent photographically. Thus, an estimation of the diagnostic reliability of ultrasound is needed before it can be used to evaluate potential human disease. Here, we evaluate how interobserver and intraobserver varia-

tion can influence the diagnosis and assessment of *O. bifurcum*-induced colonic pathology.

### MATERIALS AND METHODS

Ultrasound studies were performed in three villages within the area endemic for *O. bifurcum* in northern Ghana. Two studies evaluated the consistency of consecutive abdominal ultrasound observations for *O. bifurcum* pathology made by one observer (intraobserver variation). A third study assessed the consensus between the ultrasound observations made by two observers (interobserver variation). People were admitted into the study on a voluntary random basis after being fully informed of the purpose and nature of the tests, and they were treated for any minor illnesses. The study has been approved by the Ministry of Health Services in Upper East and Northern Region, Ghana. The informed consent procedure followed was that of witnessed verbal consent given by both the persons involved and the head of the family.

A Siemens LX portable ultrasound machine with a 5-MHz linear array transducer was used to examine the colon for characteristic anechogenic lesions. Observed nodules were counted and the largest diameter measured. The nodules were localized to a section of the colon and a skin-surface abdominal sector. The second observations were made without knowledge of the results of the first.

In the first study, two abdominal ultrasound tests were performed by the same observer (P.A. S.) on 181 people during the dry season of 1998. The examinations were completed within 28 days.

In the second study, a group of 62 people was also examined twice by the same investigator (P.A.S.) on consecutive days during the late rainy season of 1998. Only the number of nodules was recorded in the second study.

In the third study, two investigators (P.A.S. and N.S.) performed abdominal ultrasonography on 111 people during the rainy season of 1998. The people were organized into groups of five and examined in turn by the two observers, both of whom have two years of field experience in *Oesophagostomum* ultrasound. The people given a different diagnosis were later examined with both observers present.

The strength of agreement between the two sets of obser-

variations was determined by  $\kappa$  statistics. The  $\kappa$  statistics were calculated in all three studies for the prevalence and number of nodules observed. A value of 1 indicates perfect concordance between the observations.

In the first and third studies on people given a diagnosis of one nodule in both tests, a Spearman's rank correlation test was used to calculate concordance in nodule size, and the Wilcoxon's signed rank test was used to analyze the difference in size measurements. The average absolute difference in the nodule diameter measurements and its 95% confidence interval were calculated. The variance of nodule position was determined. The selection of people with one nodule was made to ensure that the same nodule was being compared.

RESULTS

The approximate prevalence of ultrasound-demonstrable pathology varied between the three communities studied: 20%, 60%, and 30%, respectively, and the lesion intensity followed the same trend. The number of nodules as recorded in both observations during the three studies is compared in Figures 1-3. The numbers in the diagonal boxes indicate perfect agreement among observations.

The value of  $\kappa$  for a positive or negative diagnosis of *O. bifurcum* colonic pathology (prevalence) was 0.82, 0.87, and 0.81 in the three studies, respectively. Analysis of the total number of nodules recorded per person (intensity of pathology) gave values for  $\kappa$  of 0.66, 0.63, and 0.71, respectively. In Study 3, the nine people given a different diagnosis were later examined with both observers present. The differences in diagnosis were attributed to two distinct reasons. An observer error was made in seven people, resulting in a nodule being seen by one of the observers but being missed by the other. Interpretation errors were made in the other two people, with the same feature being observed but a different diagnosis given: fluid collection in the angle between the psoas muscle and the iliacus bone as opposed to an *Oesophagostomum* nodule in the cecum.

The people diagnosed as having one nodule in both observations (Study 1: n = 16, Study 3: n = 17) were selected to

Number of nodules	Result in test 1							total	total
	0	1	2	3	4	5	6+		
0	23	1						24	38
1	2	9	1	1				13	
2			1	2		2		5	
3	1		1				1	3	
4						1	1	2	
5					1	1		2	
6+					1	1	11	13	
total	26	10	3	3	2	5	13	62	
	26	36							

FIGURE 2. Study 2. Number of nodules per person (> 5 grouped) in two consecutive ultrasound tests performed by one observer. The numbers in the diagonal boxes indicate perfect agreement among observations.

analyze the uniformity of nodule diameter measurement and the reliability of position allocation. Figures 4 and 5 show the measurement variation; the line indicates the position of perfect agreements. The nodule sizes observed showed a significant correlation, both in Study 1 ( $\rho = 0.96$ ) and Study 3 ( $\rho = 0.95$ ). The nodule sizes were comparable in the two sets of observations in Study 1, but in Study 3, the average size measured by Observer 2 was significantly lower compared with that measured by Observer 1 ( $P = 0.03$ ). Three and four nodules were given the same sizes in Study 1 and 3, respectively. The average absolute difference in diameter measurement between the two observations was 2.6 (Study 1) and 3.3 mm (Study 3), showing a maximum difference of 6 and 7 mm, respectively, and the upper 95% confidence intervals were 3.6 and 4.5 mm, respectively.

In Studies 1 and 3, nodules were localized to a different

Number of nodules	Result in test 1							total	total
	0	1	2	3	4	5	6		
0	142	3						145	36
1	6	16		1				23	
2	1	2	1	1				5	
3		1	1	2				4	
4				1				1	
5				1	1		1	3	
6								0	
total	149	22	2	6	1	0	1	181	
	149	32							

FIGURE 1. Study 1. Number of nodules per person in two consecutive ultrasound tests performed by one observer. The numbers in the diagonal boxes indicate perfect agreement among observations.

Number of nodules	Result by observer 1							total	total
	0	1	2	3	4	5	6		
0	71	6	1					78	36
1	2	17						19	
2			6		1			7	
3			1					1	
4				1	1		1	3	
5					1		2	3	
6								0	
total	73	23	8	1	3	0	3	111	
	73	38							

FIGURE 3. Study 3. Number of nodules per person observed by 2 ultrasound observers. The numbers in the diagonal boxes indicate perfect agreement among observations.

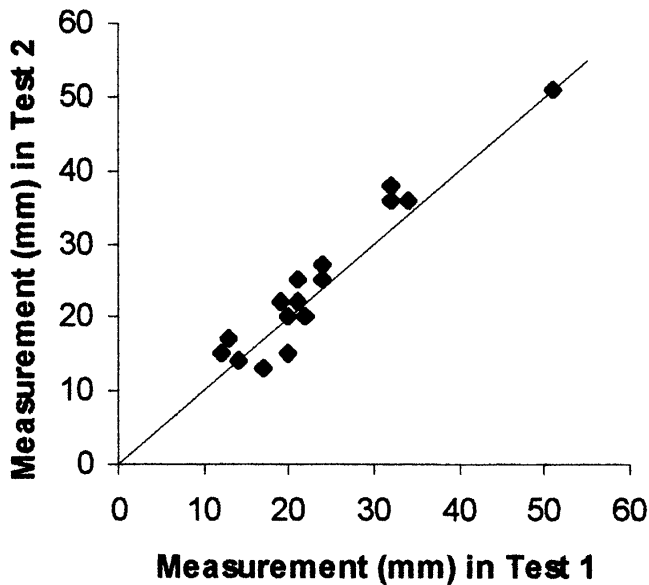


FIGURE 4. Measurement of variation in Study 1. The line indicates perfect agreement.

section of the colon in 25% ( $n = 4$ ) and 12% ( $n = 2$ ) of the observations and to a different skin-surface sector of the abdomen in 44% ( $n = 7$ ) and 47% ( $n = 8$ ) of the observations, respectively.

## DISCUSSION

To analyze the usefulness of ultrasound for the diagnosis and assessment of *O. bifurcum* induced colonic pathology, studies of interobserver and intraobserver variation were performed. A modest degree of variation was seen in all three studies. The degree of consistency between the observations is aided by the clear characteristic appearance of the nodules by ultrasound: anechogenic ovoid lesions within an echogenic colon.<sup>11</sup>

The prevalence of nodules differed little between the three studies. The most important factor in analyzing the utility of ultrasound in identifying potential *O. bifurcum*-induced disease is a positive or negative diagnosis. It is difficult to exclude the diagnosis of *O. bifurcum*-induced disease within an air-filled organ. In addition, it was difficult to quantify pathology when multiple nodules were present. This difficulty was highlighted by the moderate agreement in number of nodules in Study 2, performed in a village with a high intensity of pathology. The usefulness in clinical practice of being able to differentiate between a person having 5–6 nodules is negligible.

During post-treatment monitoring of patients, the measurement accuracy (with our machine) of 4–5 mm should be considered. Ultrasound has a lower resolution for diameter measurement compared with depth measurement, and flattening of the nodules occurred as pressure was applied to the abdomen to maintain a good skin-transducer contact. Certainty in the localization of a nodule to a definitive section of colon was ambitious, given the normal diversity of colon length and position, and it was particularly difficult when nodules were at the hepatic and splenic flexures. The variability

of the skin surface relations of the colon is large, and the borders of the abdominal sectors are not definitive to within a few millimeters. Precise localization of pathology in preparation for surgical intervention would be difficult in some cases.

Observer errors are inevitable, regardless of the resolution of the ultrasound machine. Seven of the nine differences in diagnosis made by the two observers in Study 3 were errors of this kind. Diagnosis, quantification, dimension characterization, colon section allocation, and image differentiation would be improved with higher-resolution equipment.

The minor degree of variation shown in this study for the essential aspects of the sonographic identification and assessment of *O. bifurcum*-related colonic pathology suggests that it is reliable as a diagnostic test. Its usefulness to monitor colonic recovery after treatment with albendazole has been described.<sup>3</sup> Ultrasound can contribute significantly to the diagnosis of esophagostomiasis in northern Ghana because all regional hospitals have recently been equipped with high-quality equipment and local personnel have been trained.

**Acknowledgments:** We thank Seidu Banle, Sylvia Kobb, Konlan Nimbiat, and Chief Kpamka Minpak for making the field work possible.

**Financial support:** This field work and for Clinical *Oesophagostomum* Research Project was supported by the Leverhulme Trust, the Sir Halley Stewart Trust, the Danish Bilharziasis Laboratory, and the Department of Parasitology of Leiden University.

**Authors' addresses:** P. Storey, L. van Lieshout, and A. M. Polderman, Parasitology Department, Leiden University, P.O. Box 9605, 2300RC Leiden, The Netherlands. N. Spannbrucker and E. Doebling, Board of Public Health, Neustaedter Strasse 44, 16816 Neuruppin, Germany. E. Agongo, Upper East Regional Health Services, Private Bag, Bolgatanga UER, Ghana. J. P. Zeim, School of Medicine and Health Sciences, University for Development Studies, P.O. Box 1350, Tamale, Ghana N/R. P. Magnussen, Danish Bilharziasis Laboratory, Jaegersborg Alle 1D, DK 2920 Charlottenlund, Denmark.

**Reprint requests:** A. M. Polderman, Parasitology Department, Leiden University Medical Center, P.O. Box 9600, 2300RC Leiden, The Netherlands.

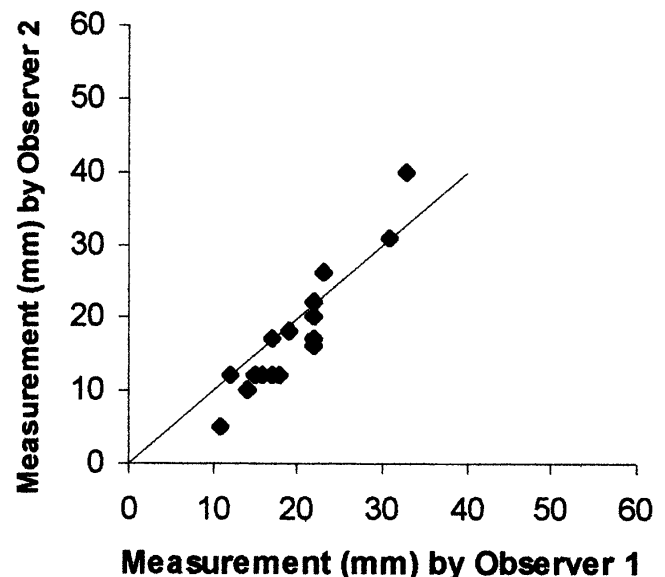


FIGURE 5. Measurement of variation in Study 3. The line indicates perfect agreement.

## REFERENCES

1. Krepel HP, Baeta S, Polderman AM, 1992. Human *Oesophagostomum* infection in northern Togo and Ghana: epidemiological aspects. *Ann Trop Med Parasitol* 86: 289–300.
2. Polderman AM, Anemana SD, Asigri V, 1999. Human oesophagostomiasis: a regional public health problem in Africa. *Parasitol Today* 15: 129–130.
3. Storey PA, Faile G, Hewitt E, Yelifari L, Polderman AM, Magnussen P, 2000. Clinical epidemiology and classification of human oesophagostomiasis. *Trans R Soc Trop Med Hyg* 94: 177–182.
4. Anthony PP, McAdam IW, 1972. Helminthic pseudotumors of the bowel: thirty-four cases of helminthoma. *Gut* 13: 8–16.
5. Haaf E, van Soest AH, 1964. Oesophagostomiasis in man in North Ghana. *Trop Geogr Med* 16: 49–53.
6. Welchman JM, 1966. Helminthic abscess of the bowel. *British Journal of Radiology* 39: 372–376.
7. Jacques JE, Lynch JB, 1964. Massive oesophagostomiasis of the colon. *Gut* 5: 80–82.
8. Leoutsakos B, Agnadi N, Kolisiatis S, 1977. Rectal bleeding due to *Oesophagostomum brumpti*: report of a case. *Dis Colon Rectum* 20: 632–634.
9. Thomas HW, 1910. The pathologic report of a case of oesophagostomiasis in man. *Ann Trop Med Parasitol* 4: 57–88.
10. Storey PA, Anemana S, van Oostayen JA, Polderman AM, Magnussen P, 2000. Ultrasound diagnosis of oesophagostomiasis. *Br J Radiol* 73: 328–332.
11. Storey PA, Faile G, Crawley D, van Oostayen JA, Anemana S, Storey PA, Polderman AM, Magnussen P, 2001. Ultrasound appearance of preclinical *Oesophagostomum bifurcum* induced colonic pathology. *Gut* 48: 565–566.