

## COMBINED ULTRASOUND AND SEROLOGIC SCREENING FOR HEPATIC ALVEOLAR ECHINOCOCCOSIS IN CENTRAL CHINA

BRIGITTE BARTHOLOMOT, DOMINIQUE A. VUITTON, SAID HARRAGA, DA ZHONG SHI, PATRICK GIRAUDOUX, GUY BARNISH, YUN HAI WANG, CALUM N. L. MACPHERSON, AND PHILIP S. CRAIG

WHO Collaborating Centre for Prevention and Treatment of Echinococcosis, University of Franche-Comté, Besançon, France; Lanzhou Medical College, Lanzhou, Gansu, PR China; Liverpool School of Tropical Medicine, Liverpool, United Kingdom; Xinjiang Medical University, Urumqi, Xinjiang, PR China; Winward Islands Research and Education Foundation, St. George's University, Grenada, West Indies; Department of Biological Sciences, Salford University, Salford, United Kingdom

**Abstract.** Alveolar echinococcosis (AE), caused by *Echinococcus multilocularis*, is a zoonotic helminthic disease that can mimic malignancy. In the 1970s, foci of the disease were found in central China. The aim of the present study was to estimate the prevalence of AE in humans in 2 districts of south Gansu Province, China, by use of ultrasound and *Echinococcus* serology. After answering an epidemiological questionnaire, 2,482 volunteers from 28 villages underwent ultrasound. Serology via enzyme-linked immunosorbent assay for antibody activity was performed on whole blood collected on filter paper in all subjects; on serum from subjects with an abnormal ultrasound image; and on randomly chosen subjects that either had no lesions or had atypical lesions. At least one (25.3%) abnormal ultrasound image was observed in 630 of the subjects screened. A typical lesion of progressive AE was found in 84 subjects (3.4%). Serologies were positive in 77 (96%) of 80 of patients who had lesions typical of progressive AE. Ultrasound is useful for screening for AE in endemic regions.

### INTRODUCTION

Alveolar echinococcosis (AE) is a relatively rare zoonotic helminthic disease that can mimic malignancy. It is caused by the development of the larval form of the canine tapeworm *Echinococcus multilocularis* in the liver. Invasion of surrounding organs, vessels, or both and distant metastases can result in obstruction of bile ducts and hepatic vessels. The disease can be severe and can lead to death within 5–10 years unless treated.<sup>1,2</sup> Progress in surgical management of the disease and the use of albendazole and mebendazole at high dosages have improved the prognosis of AE.<sup>3</sup> Early detection and treatment of AE has been shown to significantly improve survival.<sup>4,5</sup> Even though the odds of asymptomatic AE lesions progressing to severe disease are not known, it is reasonable to hypothesize that population-based screening is justified to identify asymptomatic forms of the disease in endemic countries.

Areas endemic for AE include the central part of western Europe, parts of the Near East, Russia, and central Asian Republics, northern Japan, and Alaska.<sup>1,2</sup> A focus of high prevalence of the disease in central China was suggested in the early 1970s by examination of hospital records from Gansu, Ningxia, Qinghai, and Sichuan Provinces. The high prevalence of AE in these provinces was confirmed in the 1990s by a pilot screening program that used a combination of serologic testing and ultrasound examination.<sup>6</sup> A more systematic screening program was undertaken in 1994–1997 in 2 districts of south Gansu Province (Zhang and Puma counties) for the following reasons: (1) to evaluate the limits of the endemic area in south Gansu; (2) to estimate the prevalence of *E. multilocularis* infection in this area; (3) to evaluate the feasibility and diagnostic value of the association of ultrasonography with serology for the screening of AE in rural communities, which are distant from any medical center or hospital; and (4) to identify the risk factors and transmission patterns that could be involved both in the presence of this particular disease in this area and in its suspected unusual prevalence.

Our aim here is to describe ultrasound images and the AE

pathology of asymptomatic patients identified during population screening in south Gansu and to compare the results of ultrasound to those obtained by serology by use of 4 different *Echinococcus* antigen preparations via enzyme-linked immunosorbent assay (ELISA). Detailed epidemiological transmission and ecological studies are reported elsewhere.<sup>7</sup>

### MATERIALS AND METHODS

The screening program was undertaken in 1994–1997 in cooperation with county Public Health Offices, commune (district) leaders, local doctors, and local teachers. Background information and the reasons for the study were also discussed with the local population. The study was approved by the Lanzhou Medical College Ethics and Thought Committee. Informed consent was obtained from all adult subjects and from the parents of minors after translation into the local Han Chinese dialect by staff members of Lanzhou Medical College or by local authorities.

Twenty-eight villages in Zhang and Puma Xian counties populated by Han Chinese peasants were included (Figure 1). The average population per village was 350 inhabitants (range, 200–1,500 inhabitants), and the total population was ~15,500 inhabitants. This area was ~250 km (18 hr by car) from the provincial capital, Lanzhou (34°33' N, 104°34' E), and had a mean altitude of 2,500 m. Ultrasound and serology were performed on 2,482 volunteers (mean age, 41 years; range, 11–72 years; 1,402 men, 1,077 women, with the sex of 3 not recorded). The screened population was 16% of the estimated total population, and per village, it averaged 27.5% of the village population (range, 5–92%).

After answering an epidemiological questionnaire, 4 drops of blood were taken from an earlobe of each person and placed onto Whatman number 1 filter paper (Whatman International, Maidstone, Kent, UK). Each patient underwent an ultrasound liver examination during which the clinician used a portable scanner with a 3.5-MHz transducer (Sonoline SX, Siemens, Erlangen, Germany). Examinations were performed in schools, dispensaries, or family houses. Patients

## Study area

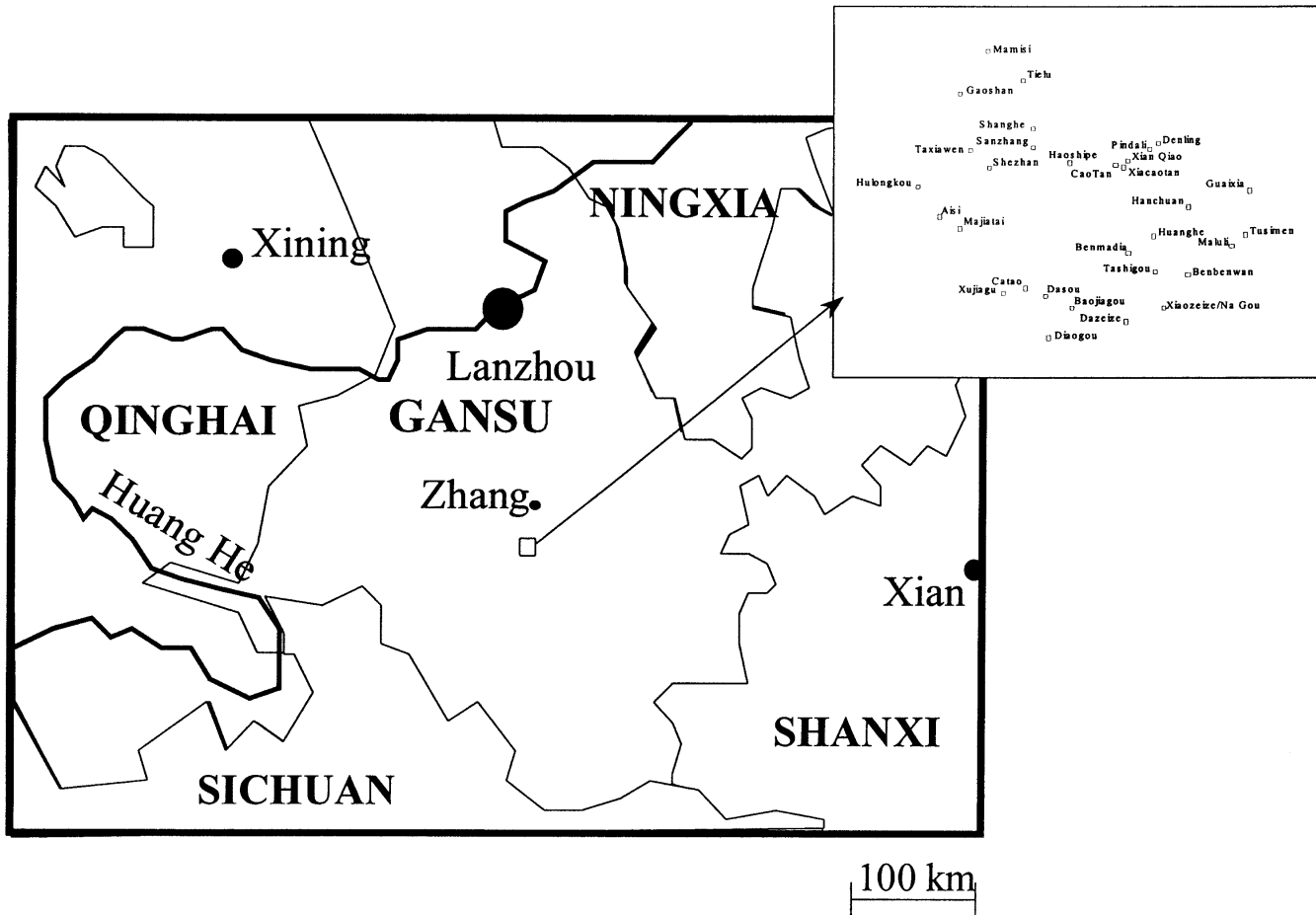

FIGURE 1. Geographic location of the screening area in Gansu Province, China.

stood for the examination. The liver was scanned in axial and longitudinal sections for the left hepatic lobe and in axial, subcostal, and recurrent subcostal sections for the right hepatic lobe. All examinations were performed or supervised (for teaching local doctors) by a single experienced examiner (B.B.). A 5-mL sample of venous blood (in addition to filter paper blood spots) was taken from patients whose ultrasound image suggested AE; from one out of every 5 people (chosen randomly) with isolated punctate calcifications in the liver; and from one out of every 50 people without evidence of liver lesions.

Serologic tests for AE antibodies were performed on whole blood after dilution of a filter paper blood disk 5 mm in diameter in 250  $\mu$ L of elution buffer. An ELISA that used a *E. multilocularis* protoscolex fraction as antigen (EmP) was used as previously described.<sup>6</sup> Serum was tested in the European laboratories, which used a crude *E. multilocularis* cyst extract (EmC), the purified *E. multilocularis* antigenic fraction Em2,<sup>8</sup> and *E. granulosus* hydatid fluid (Eg) as antigens in ELISA as previously described.<sup>4</sup>

For each antigen-antibody system used in the ELISA, sensitivity, specificity, positive predictive value, and negative predictive value were calculated for the 299 subjects who had venous blood samples drawn. Subjects with typical ul-

trasound images of AE were considered the gold standard positive cases; subjects with any other lesions or with no lesions at ultrasound examination were considered to be negative cases.

Patients with typical lesions of AE were given albendazole treatment for 6 months; local doctors were in charge of giving albendazole for the next 6 months, and the screening team distributed albendazole for previously screened patients at every survey mission. Albendazole was given to the patients according to the recommendation of the World Health Organization Working Group on Echinococcosis.<sup>3</sup> A list of patients with AE with operable hepatic lesions was scheduled for surgical intervention in Zhang, Puma, or Lanzhou hospitals.

## RESULTS

At least one abnormal ultrasound image was observed in 630 (25%) of 2,482 subjects examined. The mean time of examination was 1 min per subject and was always < 5 min, even in patients with abdominal ultrasound AE lesions in whom a careful check-up of the lesions was done. An average of 120 subjects (range, 60–180 subjects) were examined per day, typically screened over the course of 8–12

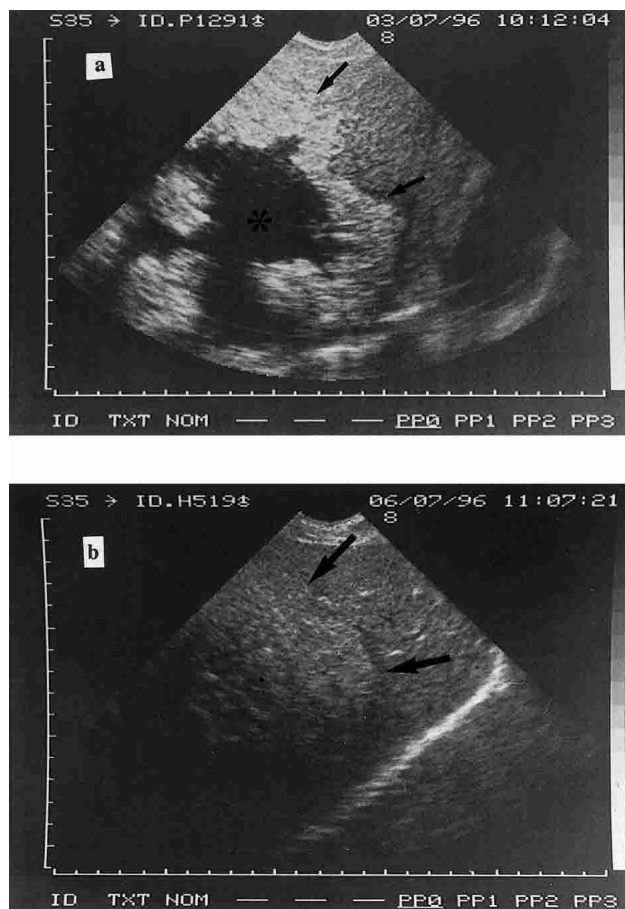


FIGURE 2. Lesions of progressive alveolar echinococcosis (AE). (a) Typical AE lesion with central necrosis: large hypoechoic area surrounded by hyperechoic parasitic tissue (arrows). (b) Infiltrating AE lesion: heterogeneous hyperechoic partially calcified area, 9 cm in diameter (arrows), without central necrosis.

days. A typical lesion of progressive AE was found in 84 subjects (3.4% of the screened population): 52 women and 32 men, mean age 38.7 years (range, 12–70 years), from 28 villages. Although cases of AE usually presented as a single individual in a household, 4 cases of apparent familial clustering occurred. In 46 patients, the ultrasound image ap-

peared similar to a neoplastic intrahepatic mass with a heterogeneous structure, mainly hyperechoic, containing scattered calcifications, and with irregular, poorly defined edges. A central necrotic cavity with a hypoechoic pseudoliquid structure and irregular borders was observed in 37 patients (Figure 2a). In 54 cases, the infiltrative lesions measured > 10 cm in diameter and invaded or surrounded vascular structures, biliary structures, or both (Figure 2b). In 29 cases, lesions were nodular, 3–6 cm in diameter in the longest dimension, and had calcifications. Twenty-four single AE lesions were located in the right hepatic lobe and 8 in the left hepatic lobe. Involvement of both right and left hepatic lobes by a single lesion was observed in 34 patients. Two or more distinct foci were observed in 18 patients: one focus in right and left hepatic lobes in 13 patients, many foci in the right hepatic lobe in 5 patients (2, 3, and 4 foci in 3, 1, and 1 patients, respectively). In 4 patients, a hyperechoic nodular lesion, 2 cm in diameter, was associated with typical lesions. In one patient, portal hypertension, ascites, and splenomegaly were present. Serology was positive with at least one of the tested antigens in 77 (96.2%) of 80 tested patients with typical lesions at ultrasound examination (Table 1).

Finding calcified lesions in the liver was common in this survey. In addition to calcifications associated with typical aspects of AE lesions, different types of calcifications were observed in 451 examined subjects. They could be divided into 2 subgroups according to size: calcified lesions, 1–3 cm in diameter (Figure 3a), and punctate calcifications, < 1 cm in diameter (Figure 3b). The first type (medium-sized calcified lesions) was observed in 19 women and 25 men (mean age, 30 years, range, 11–60 years) from 22 villages. The calcified focus was unique in 43 cases; 2 discrete foci were observed in one subject. In 40 subjects, the calcified lesion was located in the right liver and in 4 cases in the left liver. The size of the calcified focus was 1–2 cm in 20 cases and 2–3 cm in 25 subjects. A hyperechoic lesion was associated with the calcified focus in 3 subjects.

Serology on whole blood performed by use of the EmP antigen in ELISA was positive in 13 of 44 subjects with medium-sized calcifications. A more specific serology that used EmC, Em2, and Eg antigens in ELISA was performed in 43 subjects on venous blood samples and was positive in

TABLE 1  
Serological results in screened subjects with and without a suspected lesion of alveolar echinococcosis at ultrasound examination\*

| Ultrasound image                      | No. cases | No. tested sera | Serology on serum samples |      |           |            | Serology on whole blood† (EmP) |
|---------------------------------------|-----------|-----------------|---------------------------|------|-----------|------------|--------------------------------|
|                                       |           |                 | EmC+                      | Em2+ | Eg + ass. | Eg + alone |                                |
| Typical image                         | 84        | 80              | 74                        | 67   | 74        | 3          | 77                             |
| Calcified lesion (1 cm < size < 3 cm) | 44        | 43              | 13                        | 11   | 13        | 6          | 13                             |
| Punctiform calcifications             |           |                 |                           |      |           |            |                                |
| Without specific arrangement          | 363       | 64              | 2                         | 2    | 1         | 14         | 6                              |
| With linear arrangement               | 31        | 10              | 2                         | 2    | 3         | 2          | 1                              |
| With circular arrangement             | 13        | 10              | 1                         | 1    | 2         | 4          | 1                              |
| Nodular hyperechoic lesion            | 40        | 40              | 6                         | 5    | 8         | 17         | 7                              |
| Other lesions (unrelated to AE)       | 68        | 0               | 0                         | 0    | 0         | 0          | 0                              |
| No abnormal image                     | 1,852     | 52              | 1                         | 0    | 1         | 1          | 1                              |
| Total (subjects)                      | 2,482‡    | 299             | 99                        | 88   | 102       | 47         | 106                            |

\* ass. = associated with a positive serology using EmC, Em2, or both; Eg = *Echinococcus granulosus* crude antigen (hydatid fluid); EmP = *Echinococcus multilocularis* protoscolex purified antigen, according to Craig and others<sup>6</sup>; Em2 = *Echinococcus multilocularis* purified specific antigen, according to Gottstein and others<sup>7</sup>; EmC = *Echinococcus multilocularis* crude antigen.

† The data only refer to those subjects with venous blood samples.

‡ The number of subjects is lower than the number of cases because several screened subjects were found to have various types of lesions at ultrasound examination.

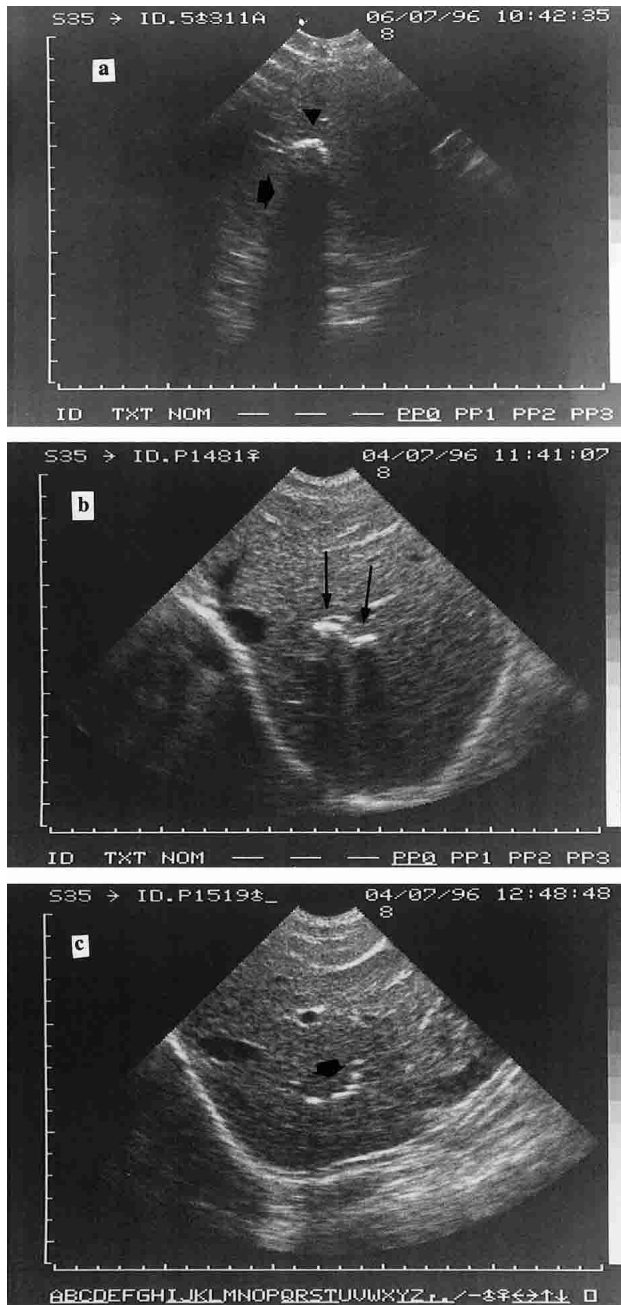


FIGURE 3. Liver calcifications. (a) Calcified lesion, 2.5 cm in diameter: hyperechoic structure (**small arrow**) with a typical posterior shadow (**big arrow**). (b) Two punctate calcifications (**arrows**). (c) Circular arrangement of several punctate calcifications (**arrow**).

19 cases; in 6 subjects, the serology was positive only when Eg was used as antigen (Table 1). In 407 subjects (15% of screened subjects), one or more punctate calcifications were observed (< 1 cm in diameter). They were solitary in 303 subjects and multiple in 104 subjects, and they were located in the right hepatic lobe in 85% of cases. In 44 subjects, these calcified lesions were linear (31 subjects) or circular (13 subjects) (Figure 3c). By use of EmC, Em2, or Eg ELISA, 17 of 64 subjects were seropositive without specific features of the calcified lesions, 4 of 10 cases with linear arrangement, and 5 of 10 cases with circular arrangement.

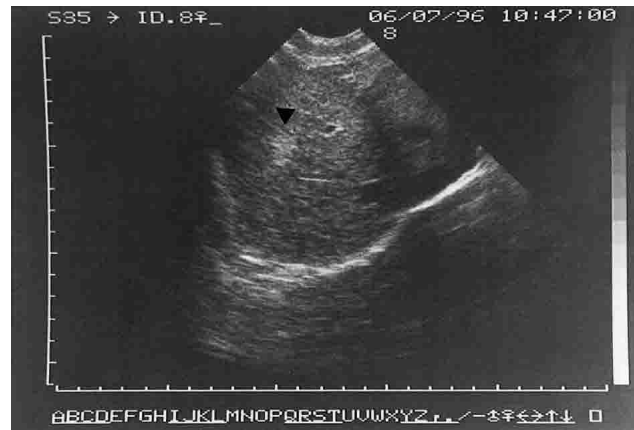

FIGURE 4. Nodular hyperechoic lesion, 1.5 by 1 cm (**arrow**).

Most often, the positive serology was observed only when Eg was used as antigen.

Well-delimited, nodular, hyperechoic, angioma-like lesions, always < 2 cm in diameter, were found in 40 subjects (20 women, 20 men; mean age, 34.6 years, range, 13–65 years), from 25 villages (Figure 4). In 37 subjects, the lesion was unique; the lesion was in the right hepatic lobe in 33 subjects; and there were 2 discrete lesions in 2 subjects, and 3 lesions in one subject. In 5 subjects, the hyperechoic lesion was associated with punctate calcifications. Serology was positive in 23 subjects; in 17 of them, antibodies were only detected by means of *E. granulosus* cyst fluid antigen (Table 1).

Other asymptomatic liver abnormalities found in the screened subjects are summarized in Table 2. They included biliary cysts in 23 subjects, gallstones in 15 subjects, kidney cysts in 12 subjects, and pleural effusion in 10 subjects. All these subjects had a negative serology.

Among the 1,852 subjects without any ultrasound abnormality in the liver, 2 were determined to have positive serology, as assessed by the EmP ELISA on filter paper blood spot eluates. Examination of one of these people a year after the first screening showed that he was seronegative, and a

TABLE 2

Asymptomatic lesions found by ultrasonography in 2,482 Han ethnicity inhabitants of Zhang and Puma Xian counties, Gansu Province, China

| Type of lesion                  | No. |
|---------------------------------|-----|
| Biliary cysts                   | 23  |
| Gallstones                      | 15  |
| Common bile duct stones         | 2   |
| Polycystic liver/kidney disease | 1   |
| Hepatic anatomical variants     | 2   |
| Postcholecystectomy aerobilia   | 1   |
| Right kidney cyst               | 12  |
| Right nephrolithiasis           | 3   |
| Right kidney angiomyolipoma     | 2   |
| Schwartz dysplasia              | 1   |
| Ascites                         | 1   |
| Right pleural effusion          | 10  |
| Retroperitoneal tumor*          | 2   |
| Ovarian cyst                    | 2   |

\* One of these subjects was symptomatic, with evidence of peritoneal carcinomatosis and chronic, progressive illness.

the first screening showed that he was seronegative, and a careful ultrasound examination could not find any suspect lesion in the liver or other abdominal locations. Among the 52 subjects without any ultrasound lesion whose serum samples were tested, 1, 0, 1, and 1 were seropositive when EmC, Em2, Eg, and EmP were used as antigens, respectively. Calculated from the data obtained in subjects whose both serum and whole blood were tested in ELISA, sensitivity was 0.92, 0.83, 0.96, and 0.96; specificity was 0.88, 0.94, 0.66, and 0.87; positive predictive value was 0.75, 0.75, 0.50, and 0.73; and negative predictive value was 0.97, 0.94, 0.98, and 0.98 when EmC, Em2, Eg, and EmP were used as antigens, respectively.

## DISCUSSION

Ultrasonography has been proven to be useful in mass screening for some infectious diseases involving the viscera, and because of its low cost, it is particularly useful in developing countries to diagnose parasitic diseases.<sup>9,10</sup> Ultrasound has been validated as being a key tool for diagnosing AE in clinical settings,<sup>1-3,11-13</sup> and preliminary reports have suggested that its use is also appropriate in the field.<sup>6</sup> This study confirms that ultrasound is feasible and efficient in screening for AE lesions and results in a rapid diagnosis of the disease at low cost for a large population in an endemic area. Ultrasound is more accurate than serology, which has been the most widely used diagnostic tool in AE screenings for the past 20 years.<sup>4,5,14,15</sup> This study also confirms the findings of an earlier ultrasound study<sup>6</sup> and demonstrates that the south Gansu area of China has the highest prevalence of AE so far described in the world: 3.4% if only typical cases are considered, compared with 0.1% in the main European endemic area of eastern France, northern Switzerland, and southern Germany.<sup>2,4</sup>

The patient population we studied accepted the ultrasound examination readily. The visual nature of the test led to overall acceptance of the screening by the population. Examination performance was fast, and the exam was compatible with the other stages of the screening (collecting answers to the epidemiologic questionnaire, taking blood drops on filter paper, and obtaining venous blood). This sequence appeared optimal because people, motivated by the visual immediacy of the ultrasound exam, were willing to answer questions and donate blood. The efficacy of an ultrasound-based screening relies, however, on the skill of the ultrasonographer because AE lesions are more complex and variable than cysts, for instance, compared with cystic echinococcosis. It must be emphasized that specific training and experience is mandatory.

Good-quality subject examination was enhanced in this survey by the absence of obesity in these rural communities of central China. The mean age and the sex ratio of the subjects with AE in this area were lower than those usually observed in Europe<sup>2,4</sup> or in Japan.<sup>5</sup> This seems to reflect special conditions of human contamination, with dogs as an important definitive host; in addition, in the population we studied, women and children were in more frequent contact with infected dogs.<sup>6,7</sup>

The sensitivity of ultrasound examination of the liver to detect lesions was good, despite the standing position of the

subjects and the short duration of the examination. Some small-sized subcapsular lesions at the periphery of the liver might have been missed, as well as some lesions masked by digestive artefacts at the inferior pole of the left hepatic lobe, segment 3, and of the right hepatic lobe, segments 6 and 7. A precise and detailed analysis of all components of the AE lesions was sometimes impaired by the presence of calcifications, characteristic of AE, that masked part of the lesion. Central necrosis, which is a common AE complication, was easy to disclose when its structure was pseudoliquid, but it was sometimes more difficult to distinguish from the hypoechoic nature of the other components (parasitic and fibrotic) of the lesions.

It must be noted that only 2 subjects had a positive screening serology via filter paper blood spot without confirmation via the presence of AE lesions at ultrasound; a careful re-examination of one of these patients did not disclose any AE lesions. Conversely, serology was negative for total blood and for serum when 4 different antigens were used in 3 (3.8%) of 80 tested patients with typical- and large-size lesions characteristic of AE; these patients would have been misdiagnosed at a serological screening. The average sensitivity of serology in this survey, which is, to our knowledge, the first to have recorded all types of liver abnormalities in all screened subjects, is similar to that observed in hospital-based series of patients with AE.<sup>2,3</sup>

Taking typical lesions at ultrasound as the gold standard for the diagnosis of AE, sensitivity and specificity of the EmP ELISA performed on whole blood taken on filter paper were the same as or better than the EmC and Eg ELISA used in this and other screening programs.<sup>4</sup> Em2 ELISA serology was negative in 13 patients with typical lesions. Em2 ELISA had the lowest sensitivity and positive predictive value. In addition to typical AE lesions, EmC—and especially Eg—ELISA were positive in a number of patients with calcifications (44% of calcifications > 1 cm, and 31% of punctate calcifications) and in 57% of cases with a nodular hyperechoic lesion. Such seropositive subjects were more highly represented in the subgroup with calcified lesions and hyperechoic lesions in the liver than among those without any lesions. This suggests that the use of crude antigens in ELISA may find “abortive” AE lesions and early cases before the development of typical images. Abortive cases have been reported in screening programs that are based on serology, followed by ultrasound and computed tomography confirmation in hospitals.<sup>4,16</sup> The number of such cases, however, was far lower than that observed in this ultrasound-serology survey, which suggests that spontaneously abortive forms of AE can be fairly frequent.

Until this study, the actual number of subjects living in areas endemic for AE with liver calcifications that could represent abortive cases long after the disappearance of specific antibodies in the serum was unknown. Large-sized calcifications seemed undoubtedly related to AE, in some cases with highly positive serology. Coexistence of viable progressive lesions cannot be ruled out; this could be checked only by use of computed tomography or magnetic resonance imaging. The origin of the numerous punctate calcifications is more open to debate: tuberculosis is rare in this community and should have been visualized as multiple calcifications scattered in the liver; ascaris infection seems to be the

most probable differential diagnosis because serological cross-reactivity, although rare, cannot be totally excluded.<sup>17</sup>

Etiology of the nodular hyperechoic lesions could only be suggested further by magnetic resonance imaging<sup>18</sup> or confirmed by surgical biopsy. Both are difficult because these villages are far from radiological or surgical facilities. Prevalence of hemangiomas of the liver averages 2% in patients with an ultrasound examination in Western countries<sup>19</sup>; their prevalence in Chinese populations is unknown. In our survey, more than half of the subjects with such a lesion were found to have positive serology (most of them were assessed by means of Eg ELISA), and in 4 patients, a hyperechoic nodule was associated with a typical form. Hyperechoic nodular appearance of AE lesions has been reported to correspond to early stages of the disease on the basis of observations of recurrence of AE after a so-called radical resection<sup>20</sup> or after transplantation from perihepatic remnants.<sup>21,22</sup> It must be noted that in our experience, recurrences of AE after transplantation were associated with a positive Eg ELISA serology before the appearance of serum antibodies detected by EmC, and especially Em2, antigens.<sup>21,22</sup> At least a part of the nodular hyperechoic lesions observed in this screening could be related to AE. Because these lesions develop slowly, ultrasound and serological follow-up of these subjects will be performed every 2 years.

Mass screening for AE by means of ultrasound as a first-intention examination in populations far from any hospital facilities is not only feasible and well accepted by the patient population, but it is also more efficient than serology-based screenings. Serology that uses the EmP antigen in ELISA on whole blood spots may be a useful complementary test. To confirm the interpretation of isolated calcifications as suggestive of abortive forms and of hyperechoic nodules as representative of early cases, prolonged follow-up of the screened subjects will be necessary. Such studies will provide a more precise assessment of the prevalence of AE in this Chinese community, which appears to have the highest *E. multilocularis* infection rate in the world.

**Acknowledgments:** We thank Annie Baud and Michel Gaudron for their help in the preparation of the article in manuscript and Prof. Bruno Gottstein (Institute of Parasitology, Bern, Switzerland) for his gift of Emc, Em2, and Eg antigens.

**Financial support:** This study was supported by the European Commission, DG XII, Sciences and Technology for Development 3, TS 3-CT 94-0270 grant, by the Region de Franche-Comté, and Franche-Comté University, France.

**Authors' addresses:** Brigitte Bartholomot, Said Harraga, Patrick Giraudoux, and Dominique A. Vuitton, WHO Collaborating Centre for Prevention and Treatment of Human Echinococcosis, SERF Research Unit EA 2276 and ISTE, University of Franche-Comté, 25030 Besançon, France. Da Zhong Shi, Lanzhou Medical College, Lanzhou, Gansu, PR China. Guy Barnish, Liverpool School of Tropical Medicine, Liverpool, UK. Yun Hai Wang, Xinjiang Medical University, 8 Xinyi Road, Urumqi, Xinjiang, 830054 PR China. Calum N. L. Macpherson, Winward Islands Research and Education Foundation, St. George's University, Grenada, West Indies. Philip S. Craig, Department of Biological Sciences, Salford University, Salford, UK.

**Reprint requests:** Dominique Angèle Vuitton, WHO Collaborating Centre for Prevention and Treatment of Echinococcosis, Faculté de Médecine et de Pharmacie de l'Université de Franche-Comté, F-25030 Besançon, France, Telephone: 33-3-81-66-55-70, Fax: 33-3-81-66-55-70, E-mail: dominique.vuitton@univ-fcomte.fr.

## REFERENCES

1. Miguet JP, Bresson-Hadni S, Vuitton DA, 1991. Alveolar echinococcosis. McIntyre B, Benhamou JP, Bircher J, Rizetto M, Rodes J, eds. *Oxford Textbook of Clinical Hepatology*. Oxford: Oxford University Press, 721–725.
2. Ammann RW, Eckert J, 1996. Cestodes. *Echinococcus*. *Gastroenterol Clin North Am* 25: 655–689.
3. WHO Informal Working Group on Echinococcosis, 1996. Guidelines for treatment of cystic and alveolar echinococcosis in humans. *Bull World Health Organ* 74: 231–242.
4. Bresson-Hadni S, Laplante JJ, Lenys D, Rohmer P, Gottstein B, Jacquier P, Mercet J, Meyer JJ, Miguet JP, Vuitton DA, 1994. Seroepidemiologic screening of *Echinococcus multilocularis* infection in a European area endemic for alveolar echinococcosis. *Am J Trop Med Hyg* 51: 837–846.
5. Sato N, Namieno T, Furuya K, Takahashi H, Yamashita K, Uchino J, Suzuki K, 1997. Contribution of mass screening system to resectability of hepatic lesions involving *Echinococcus multilocularis*. *J Gastroenterol* 32: 351–354.
6. Craig PS, Deshan L, Macpherson CNL, Dazhong S, Reynolds D, Barnish G, Gottstein B, Zhirong W, 1992. A large focus of alveolar echinococcosis in central China. *Lancet* 340: 826–831.
7. Craig PS, Giraudoux P, Shi DZ, Bartholomot B, Barnish G, Delattre P, Quere JP, Harraga S, Bao G, Wang Y, Lu F, Ito A, Vuitton DA, 2000. An epidemiological and ecological study of human alveolar echinococcosis transmission in south Gansu, China. *Acta Trop* 77: 167–177.
8. Gottstein B, 1985. Purification and characterization of a specific antigen from *Echinococcus multilocularis*. *Parasite Immunol* 7: 201–212.
9. Macpherson CNL, 1992. Use of ultrasound in the diagnosis of parasitic disease. *Trop Doct* 22: 14–20.
10. Sato H, Kamiya H, Grauert MR, Stern D, Altamirano Z, Perdomo R, Carmona C, Carbo A, Alvarez C, Monti J, Sakai H, Oku Y, Kamiya M, 1996. Comparison of serodiagnostic tests and ultrasonography for cystic hydatidosis in an epidemiological study of rural Uruguay. *J Parasitol* 82: 852–854.
11. Didier D, Weiler S, Rohmer P, Lassegue A, Deschamps JP, Vuitton D, Miguet JP, Weill F, 1985. Hepatic alveolar echinococcosis: correlative US and CT study. *Radiology* 154: 179–186.
12. Weill FS, Racle A, Morin M, Rohmer P, Gigandet S, 1991. Multilocular hepatic echinococcosis (alveolar echinococcosis): duplex and color Doppler vascular evaluation in comparison with computed tomography and angiography in 18 patients. *Diagn Int Radiol* 3: 39–45.
13. Choji K, Fujita N, Chen M, Spiers AS, Morita Y, Shinohara M, Nojima T, Irie G, 1992. Alveolar hydatid disease of the liver: computed tomography and transabdominal ultrasound with histopathological correlation. *Clin Radiol* 46: 97–103.
14. Gottstein B, Lengeler C, Bachmann P, Hagemann P, Kocher P, Brossard M, Witassek F, Eckert J, 1987. Sero-epidemiological survey for alveolar echinococcosis (by Em2-ELISA) of blood donors in an endemic area of Switzerland. *Trans R Soc Trop Med Hyg* 81: 960–964.
15. Gottstein B, Schantz PM, Wilson JF, 1985. Serological screening for *Echinococcus multilocularis* infections with ELISA. *Lancet* 8437: 1097–1098.
16. Rausch RL, Wilson JF, Schantz PM, McMahon BJ, 1987. Spontaneous death of *Echinococcus multilocularis*: cases diagnosed serologically (by Em2 ELISA) and clinical significance. *Am J Trop Med Hyg* 36: 576–585.
17. Gottstein B, 1992. *Echinococcus multilocularis* infection: immunology and immunodiagnosis. *Adv Parasitol* 31: 321–380.
18. Bartholomot B, Bresson-Hadni S, Manton G, Vuitton DA, Kastler B, 1997. Magnetic resonance (MR) imaging in echinococcosis. Menezes da Silva A, Nunes JL, eds. *Archivos Internacionales de la Hidatidosis vol XXXII*. Lisbon: International Association of Hydatidology, 189–192.
19. Mathieu D, Rahmouni A, Anglade MC, Radier C, Dhina Z, Golli M, Paret M, Genin G, Vasile N, 1994. Tumeurs bénignes du foie. *Encyclopédie Médico-Chirurgicale-Radiodiagnostic*

- Appareil Digestif*. Paris: Editions Techniques, 33-520-A-30, 14 p.
20. Ammann RW, Ilitsch N, Marincek B, Freiburghaus AU, 1994. Effect of chemotherapy on the larval mass and the long-term course of alveolar echinococcosis. *Hepatology* 19: 735–734.
  21. Bresson-Hadni S, Franza A, Miguet JP, Vuitton DA, Lenys D, Monnet E, Landecy G, Paintaud G, Rohmer P, Becker MC, Manton G, Gillet M, 1991. Orthotopic liver transplantation for incurable alveolar echinococcosis of the liver: report of 17 cases. *Hepatology* 13: 1061–1070.
  22. Bresson-Hadni S, Vuitton DA, Bartholomot B, Godart D, Meyer JP, Hrusovsky S, Becker MC, Manton G, Lenys D, Miguet JP, 2000. A twenty-year history of alveolar echinococcosis in humans. Analysis of a series of 117 patients from eastern France. *Eur J Gastroenterol Hepatol* 12: 327–336.