

## Case Report: Two Cases of Recurring *Ovale* Malaria in Sarawak, Malaysia, after Successful Treatment of Imported *Plasmodium falciparum* Infection

Jonathan Wee Kent Liew,<sup>1</sup> Choo Huck Ooi,<sup>2</sup> Georges Snounou,<sup>3</sup> and Yee Ling Lau<sup>1\*</sup>

<sup>1</sup>Department of Parasitology, Faculty of Medicine, University of Malaya, Kuala Lumpur, Malaysia; <sup>2</sup>Vector Borne Diseases Section, Sarawak Health Department, Kuching, Malaysia; <sup>3</sup>CEA-Université Paris Sud 11-INSERM U1184, Immunology of Viral Infections and Autoimmune Diseases (IMVA), Infectious Disease Models and Innovative Therapies (IDMIT) Department, Institut de Biologie François Jacob (IBFJ), Direction de la Recherche Fondamentale (DRF), Fontenay-aux-Roses, France

**Abstract.** Here are two cases of recurring *ovale* malaria in Sarawak, Malaysia, that are likely relapses that occurred 1–2 months after successful treatment of the initial imported *falciparum* malaria with artemisinin-based combined therapy. The patients have no history or recollection of previous malaria episodes. These cases add to the limited evidence on the relapsing nature of *Plasmodium ovale*, after a febrile episode. In regions where *P. ovale* is not known to be autochthonous, active follow-up of treated imported malaria patients is highly recommended following their return, particularly to areas nearing or having achieved elimination.

### CASE REPORT

A 51-year-old Chinese man presented with a fever, headache, rigor, and nausea 3 days after returning to Sarawak, Malaysia, from Liberia in June 2017 (Case 1). He had been working in the timber industry for one and a half years in Liberia. Blood films for malaria parasites (BFMP) indicated *falciparum* infection with 1,294 asexual parasites/ $\mu$ L of blood. The patient was managed according to the 2013 Management Guidelines of Malaria in Malaysia. For uncomplicated *falciparum* malaria, Riamet<sup>®</sup> (20 mg artemether/120 mg lumefantrine; Riamet<sup>®</sup>, Novartis, UK) was prescribed for 3 days with a total of six doses and a dose of primaquine (0.75 mg/kg; max 45 mg) on the first day of treatment. The patient received initial four tablets of Riamet per dose, followed by a second dose 8 hours later, and two doses per day for the following 2 days. Treatment with artemisinin-based combined therapy (ACT) reduced the parasite density to 80 parasites/ $\mu$ L of blood one day later. The patient then followed the recommended follow-up monitoring points of day 3, day 7, day 14, day 21, and day 28. Parasites were not found during follow-ups until he experienced a fever on day 26 after ACT. On day 28 of follow-up, BFMP was positive for *Plasmodium ovale*, with 5,822 asexual parasites/ $\mu$ L and 118 gametocytes/ $\mu$ L of blood. He was subsequently treated with Riamet for 3 days (as earlier) and primaquine (0.5 mg/kg) for 14 days. The patient was cured. During the monthly follow-up for 11 months, no parasites were observed in the blood films for up to 5 months after treatment. During his stay in Sarawak, he had only traveled to non-receptive areas.

Another case (Case 2) was recorded on November 29, 2017, as an imported *falciparum* malaria in a patient returning from Equatorial Guinea, with a parasite density of 4,123 asexual parasites/ $\mu$ L of blood. The patient was treated as in Case 1. On January 24, 2018, approximately 2 months after the first malaria episode, the patient presented with a fever. Subsequently, a BFMP was performed and *P. ovale* was detected. The parasite density was 515 asexual parasites/ $\mu$ L and 68 gametocytes/ $\mu$ L of blood. Treatment with Riamet and primaquine was similarly given as in Case 1 during the second

episode. Within this period of time, the patient resided in a non-receptive area in Sarawak and had no travel history to any receptive area.

Microscopic examination of Giemsa-stained blood smears (Figure 1) yielded a diagnosis of imported *Plasmodium falciparum* infection and relapse of *P. ovale* for both cases. Both blood smears were read first by a microscopist from the admitting hospital and confirmed by experienced microscopists at the Divisional and State Malaria Laboratory. A retrospective nested polymerase chain reaction (PCR) assay targeting the malaria parasites' 18S small-subunit rRNA gene<sup>1,2</sup> was performed on DNA extracted from blood spots collected on the day following ACT administration for the primary admission and for the recurrence episodes for both cases. Briefly, DNA was extracted from two blood spots which were cut into pieces, each from the admission and recurrence episodes, using Qiagen DNeasy Blood and Tissue kit (Qiagen, Hilden, Germany). The initial genus-specific PCR was performed using 4  $\mu$ L of DNA in a 25- $\mu$ L reaction volume, followed by species-specific PCR using 4  $\mu$ L of the PCR product from the initial PCR. The presence of *P. falciparum* and *P. ovale* was indicated by 206 bp and 659–662 bp products, respectively, after agarose gel electrophoresis. Polymerase chain reaction confirmed *falciparum* malaria on admission with the absence of *P. ovale* and infection with *P. ovale wallikeri* only in the recurrence episode for Case 1. This is the second report of an imported *P. ovale wallikeri* infection in Malaysia.<sup>3</sup> However, that of Case 2 was negative.

### DISCUSSION

There are increasing reports of *ovale* malaria, caused by *P. ovale wallikeri* and *P. ovale curtisi*, among travelers to sub-Saharan Africa, Indonesia, Papua New Guinea, and India.<sup>4</sup> *Plasmodium ovale* is believed to be capable of causing relapses (due to liver hypnozoites) months to years after the primary infection.<sup>5</sup> Furthermore, coinfections of *P. ovale* with other malaria species, especially *P. falciparum*, are frequent in malaria-endemic areas.<sup>6</sup> Two cases similar to those presented here were recently reported.<sup>7,8</sup> The patients were admitted in Brazil and Canada, respectively, where there is no *ovale* malaria transmission. Recurrent *ovale* infections following successful treatment of *falciparum* malaria could be a

\* Address correspondence to Yee Ling Lau, Department of Parasitology, Faculty of Medicine, University of Malaya, Kuala Lumpur 50603, Malaysia. E-mail: lauyeeeling@um.edu.my

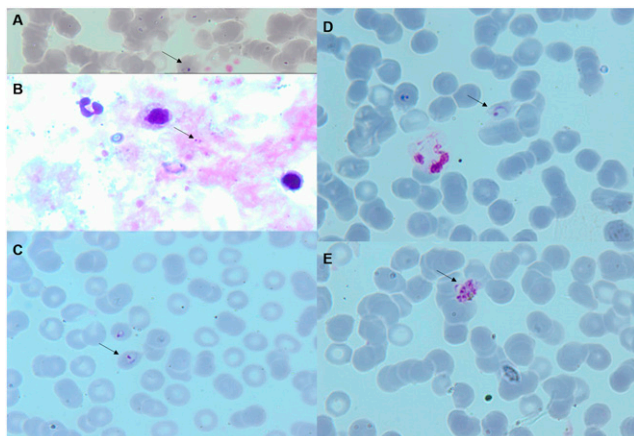


FIGURE 1. Representative microphotographs of Giemsa-stained blood films of the patient in Case 1 viewed under  $\times 1,000$  magnification. (A) *Plasmodium falciparum* ring-stage parasite in thin blood smear. (B) *Plasmodium falciparum* ring-stage parasite in thick blood smear. (C and D) *Plasmodium ovale* ring-stage parasites in oval and fimbriated red blood cells. (E) Schizont of *P. ovale* with approximately eight nuclei. This figure appears in color at [www.ajtmh.org](http://www.ajtmh.org).

new infection, a recrudescence, a relapse, or a delayed primary attack (the last two derived from hypnozoites).

A new infection of *P. ovale* is highly unlikely in the two cases reported here because *P. ovale* is not known to be autochthonous in Malaysia, including Sarawak.<sup>3</sup> Furthermore, a retrospective PCR screening of 44 blood spots collected between 2015 and 2017 from microscopically determined *Plasmodium vivax*-infected patients in Sarawak (a parasite species that is morphologically similar to *P. ovale*) showed only one misdiagnosed imported ovale malaria case from Gabon (Y. L. Lau, unpublished data). Therefore, the possibility of misdiagnosing ovale malaria as vivax malaria in Sarawak is low.

Coinfections are frequent in endemic areas, although *Plasmodium malariae* and *P. ovale*, whose parasitemias are often very low or below the detection limit, are easily overlooked microscopically<sup>6,9,10</sup> and are often found with *P. falciparum* following PCR detection.<sup>11,12</sup> For Case 1, a patent coinfection on admission is unlikely because only *P. falciparum* was detected by the PCR assay and only *P. ovale wallikeri* in the recurrent episode sample. It is unfortunate that the sample from Case 2 failed to amplify. Because the blood spots were collected on the day following ACT administration, it is likely that the parasite levels in this case had sunk below the level of detection, although it might also be due to degradation of the DNA before receipt of the sample for processing. A coinfection on admission or a recrudescence from an existing low-grade ovale infection would imply that ACT administration, which has effectively eliminated *P. falciparum*, failed to clear *P. ovale*. This is unlikely as ACT is considered highly efficacious for non-falciparum malaria<sup>13</sup>; moreover, the recurrent *P. ovale* episodes in the two cases presented here were rapidly cleared by the ACT administered.

Thus, the recurring ovale malaria in both cases are most likely relapses from hypnozoites even though the patients did not recall any previous clinical malaria episodes. The timing of these relapses is consistent with previously observed median times between a primary attack of *P. ovale* and first relapse of 17 weeks (range 2–60 weeks).<sup>4</sup> Our observations are also consistent with the suggestion that hypnozoite

activation to cause relapse may be induced by fever due to a bacterial, viral, or malarial infection.<sup>7,14,15</sup> Despite the paucity of observations, as compared with those of *P. vivax* malaria, suggestions that *P. ovale* does not produce hypnozoites are likely to be incorrect.<sup>4,16</sup> In a recent report, convincing evidence for relapse in *P. ovale* infection showed that the reappearing *P. ovale* parasites following supervised treatment of a patient in a non-endemic region were of the same genotype as that of the parasites found in the primary episode.<sup>17</sup> A delayed primary attack originating from hypnozoites, as described for some *P. vivax* malaria strains from temperate regions, cannot be formally discounted.<sup>14</sup> However, in previous reports of such delayed attacks, antimalarial prophylaxis during initial exposure was noted, and a clinically mild primary episode could not be excluded.

Clinical, parasitological, and biological investigations on hypnozoites and relapses are restricted by logistical and ethical considerations, yet this phenomenon is of importance in the context of malaria control and elimination strategies. The two cases reported here add to the small number of such observations on *P. ovale* and provide evidence to support the relapsing nature of this parasite species. For patients returning from ovale-endemic areas, and in particular to regions where malaria transmission is possible, clinicians should keep in mind the possibilities of coinfection or prepatent infection with *P. ovale*, especially as prophylactic medications (such as atovaquone–proguanil combination) have little effect on the hypnozoite.<sup>18</sup> Because *P. ovale* and *P. falciparum* are fairly common and co-circulate in endemic areas such as sub-Saharan Africa, diagnosis of *P. falciparum* infection alone from these areas may not exclude a subsequent recurrence of malarial infection by *P. ovale*. Provided adequate screening for glucose-6-phosphate dehydrogenase, primaquine could be considered for routine administration to those presenting with malaria on their return from endemic areas, although cases of primaquine failure to prevent ovale relapses have been reported.<sup>4</sup> Ultimately, it will be important to maintain an active follow-up for at least 3 months for patients returning from areas endemic for relapsing malaria species.<sup>8</sup>

Received April 22, 2019. Accepted for publication September 6, 2019.

Published online October 7, 2019.

Acknowledgments: We would like to thank the director general of Health Malaysia for his permission to publish this article.

Financial support: Y. L. L. is supported by the Ministry of Education Malaysia (long-term research grant scheme LR002D-2018). G. S. was supported by a grant from the Agence Nationale de la Recherche, France (ANR-17-CE13-0025-01).

Authors' addresses: Jonathan Wee Kent Liew and Yee Ling Lau, Department of Parasitology, Faculty of Medicine, University of Malaya, Kuala Lumpur, Malaysia, E-mails: jonathanliew@um.edu.my, jon\_wkent@hotmail.com, and lauyeeling@um.edu.my. Choo Huck Ooi, Vector Borne Diseases Section, Sarawak Health Department, Ministry of Health Malaysia, Kuching, Malaysia, E-mail: ooi.choo.huck@gmail.com. Georges Snounou, CEA-Université Paris Sud 11-INERM U1184, Immunology of Viral Infections and Autoimmune Diseases (IMVA), IDMIT Department, IBFJ, DRF, Fontenay-aux-Roses, France, E-mail: georges.snounou@cea.fr.

## REFERENCES

1. Singh B, Bobogare A, Cox-Singh J, Snounou G, Abdullah MS, Rahman HA, 1999. A genus- and species-specific nested

- polymerase chain reaction malaria detection assay for epidemiologic studies. *Am J Trop Med Hyg* 60: 687–692.
2. Calderaro A, 2007. Genetic polymorphisms influence *Plasmodium ovale* PCR detection accuracy. *J Clin Microbiol* 45: 1624–1627.
  3. Liew JW, Mahmud R, Tan LH, Lau YL, 2016. Diagnosis of an imported *Plasmodium ovale wallikeri* infection in Malaysia. *Malar J* 15: 8.
  4. Groger M, Fischer HS, Veletzky L, Lalremruata A, Ramharter M, 2017. A systematic review of the clinical presentation, treatment and relapse characteristics of human *Plasmodium ovale* malaria. *Malar J* 16: 112.
  5. Collins WE, Jeffery GM, 2005. *Plasmodium ovale*: parasite and disease. *Clin Microbiol Rev* 18: 570–581.
  6. Smith A, Denholm J, Shortt J, Spelman D, 2011. *Plasmodium* species co-infection as a cause of treatment failure. *Travel Med Infect Dis* 9: 306–309.
  7. Lupi O, Ridolfi F, da Silva S, Zanini GM, Lavigne A, Nogueira RMR, da Cruz Mde F, Daniel-Ribeiro CT, Brasil P, 2016. Dengue infection as a potential trigger of an imported *Plasmodium ovale* malaria relapse or a long incubation period in a non-endemic malaria region. *Int J Infect Dis* 44: 20–24.
  8. Senn H, Alattas N, Boggild AK, Morris SK, 2014. Mixed-species *Plasmodium falciparum* and *Plasmodium ovale* malaria in a paediatric returned traveller. *Malar J* 13: 78.
  9. Bichara C, Flahaut P, Costa D, Bienvenu A-L, Picot S, Gargala G, 2017. Cryptic *Plasmodium ovale* concurrent with mixed *Plasmodium falciparum* and *Plasmodium malariae* infection in two children from Central African Republic. *Malar J* 16: 339.
  10. Mueller I, Zimmerman PA, Reeder JC, 2007. *Plasmodium malariae* and *Plasmodium ovale*—the “bashful” malaria parasites. *Trends Parasitol* 23: 278–283.
  11. Dinko B, Oguike MC, Larbi JA, Bousema T, Sutherland CJ, 2013. Persistent detection of *Plasmodium falciparum*, *P. malariae*, *P. ovale curtisi* and *P. ovale wallikeri* after ACT treatment of asymptomatic Ghanaian school-children. *Int J Parasitol Drugs Drug Resist* 3: 45–50.
  12. Miller RH, Obuya CO, Wanja EW, Ogutu B, Waitumbi J, Luckhart S, Stewart VA, 2015. Characterization of *Plasmodium ovale curtisi* and *P. ovale wallikeri* in western Kenya utilizing a novel species-specific real-time PCR assay. *PLoS Negl Trop Dis* 9: e0003469.
  13. Visser BJ, Wieten RW, Kroon D, Nagel IM, Bèlard S, van Vugt M, Grobusch MP, 2014. Efficacy and safety of artemisinin combination therapy (ACT) for non-*falciparum* malaria: a systematic review. *Malar J* 13: 463.
  14. White NJ, 2011. Determinants of relapse periodicity in *Plasmodium vivax* malaria. *Malar J* 10: 297.
  15. Douglas NM, Nosten F, Ashley EA, Phaiphun L, van Vugt M, Singhasivanon P, White NJ, Price RN, 2011. *Plasmodium vivax* recurrence following *falciparum* and mixed species malaria: risk factors and effect of antimalarial kinetics. *Clin Infect Dis* 52: 612–620.
  16. Richter J, Franken G, Mehlhorn H, Labisch A, Häussinger D, 2010. What is the evidence for the existence of *Plasmodium ovale* hypnozoites? *Parasitol Res* 107: 1285–1290.
  17. Veletzky L, Groger M, Lagler H, Walochnik J, Auer H, Fuehrer HP, Ramharter M, 2018. Molecular evidence for relapse of an imported *Plasmodium ovale wallikeri* infection. *Malar J* 17: 78.
  18. Gallien S, Taieb F, Schlemmer F, Lagrange-Xelot M, Atlan A, Sarfati C, Molina JM, 2008. Failure of atovaquone/proguanil to prevent *Plasmodium ovale* malaria in traveler returning from Cameroon. *Travel Med Infect Dis* 6: 128–129.