Am. J. Trop. Med. Hyg., 68(3), 2003, pp. 325–328
Copyright © 2003 by The American Society of Tropical Medicine and Hygiene

INTERLEUKIN-8, TUMOR NECROSIS FACTOR-α, AND LACTOFERRIN IN IMMUNOCOMPETENT HOSTS WITH EXPERIMENTAL AND BRAZILIAN CHILDREN WITH ACQUIRED CRYPTOSPORIDIOSIS

CIRLE S. ALCANTARA, CHANG-HUN YANG, THEODORE S. STEINER, LEAH J.BARRETT, ALDO A. M. LIMA, CYNTHIA L. CHAPPELL, PABLO C. OKHUYSEN, A. CLINTON WHITE, JR., AND RICHARD L. GUERRANT

Division of Geographic and International Medicine, Department of Medicine, University of Virginia School of Medicine, Charlottesville, Virginia; Division of Gastroenterology and Hepatology, Department of Internal Medicine, University of DongGuk College of Medicine, Kyungju; Korea; Clinical Research Unit, Federal University of Ceará, Fortaleza, Ceará, Brazil; Center for Infectious Diseases, University of Texas School of Public Health; Houston, Texas; Division of Infectious Diseases, University of Texas-Houston Medical School; Houston, Texas; Infectious Diseases Section, Department of Medicine, Baylor College of Medicine, Houston, Texas

Abstract. To examine the importance of intestinal inflammation in the diagnosis and pathogenesis of human cryptosporidiosis, stools of healthy adult volunteers before and after experimental infection were tested for fecal lactoferrin, interleukin-8 (IL-8), and tumor necrosis factor-α (TNF-α). Stool samples of Brazilian children with well-defined *Cryptosporidium* infection, with or without diarrhea, were also tested for IL-8 and TNF-α. Only one of the 14 volunteers challenged with *Cryptosporidium* had increased fecal lactoferrin. However, of 17 stool specimens from children with only *Cryptosporidium* infection from a previous study, 12 had mild to moderately elevated lactoferrin despite negative work-up for inflammatory enteritides. One of 10 adult volunteers who developed diarrhea with experimental cryptosporidiosis and three of 11 children with cryptosporidiosis and diarrhea had detectable fecal IL-8. The level of TNF-α was increased only in one of 14 volunteers and in none of the children. Although considered relatively non-inflammatory, cryptosporidiosis is often associated with mild inflammation, especially in children in an endemic area.

INTRODUCTION

Cryptosporidium spp. are coccidian parasites that have been known to be pathogenic to animals and humans. Cryptosporidiosis is recognized as a cause of severe prolonged watery diarrhea in patients with the acquired immunodeficiency syndrome and also as a cause of sporadic and epidemic diarrhea in both immunocompetent and immunocompromised hosts. In children, cryptosporidiosis has been associated with persistent diarrhea and malnutrition.[1,2]

The pathophysiology of diarrhea induced by *Cryptosporidium* is not clear. The parasite is primarily intracellular, but is extracytoplasmic in the intestinal epithelium of the host. It elicits a predominantly secretory diarrhea. At least three types of mechanisms have been proposed[3]: parasite-induced damage of intestinal architecture leading to malabsorption and osmotic diarrhea; the release of metabolites of inflammatory or hormonal nature (or both) as part of the host response to the infection, which in turn may induce intestinal secretion possibly associated with malabsorption; and parasite production of an enterotoxic moiety responsible for secretory diarrhea.[3]

The purpose of this study was to investigate indications of an inflammatory component in experimentally acquired *C. parvum* infection in healthy adult volunteers and in naturally acquired cryptosporidial diarrhea in Brazilian children. Stool samples were assayed for interleukin-8 (IL-8), tumor necrosis factor-α (TNF-α), and lactoferrin, which were used as indicators of inflammation.

MATERIALS AND METHODS

Informed consent was obtained from the adult volunteers and parents or guardians of the children. The human experimentation guidelines of the U.S. Department of Health and Human Services and Federal University of Ceará were followed in this study.

Volunteer studies. Healthy, adult volunteers were tested for anti-*C. parvum* IgM and IgG by enzyme-linked immunosorbent assay using an antigen preparation from disrupted oocysts.[4] Subjects were grouped by serostatus and challenged with known numbers of either the Iowa or TAMU isolate of *C. parvum* (bovine genotype) oocysts. Seropositive volunteers received a median dose of 500 (range = 100–1,000) oocysts of the Iowa isolate (50% infectious dose [ID_{50}] = 10). There were no significant differences in the rate and intensity of infection between seronegative and seropositive volunteers. Volunteers were then monitored over a 6–8-week period for illness and infection parameters. Two or more stool samples were selected from nine antibody-negative and six antibody-positive volunteers. Stool samples included one sample from days 0–2 (before symptoms) and one or more samples during and following the diarrheal episode. For those subjects that did not develop diarrhea, stool samples were selected from the time period in which illness typically occurred. Clinical microbiologic work-up confirmed that no other known enteric pathogens were present in subjects who experienced a diarrheal illness. *Cryptosporidium parvum* oocysts in stool were detected by direct immunofluorescence.

Brazilian cohort. Stool specimens were screened for enteric bacterial, viral, or parasitic pathogens as a part of a cohort study of 189 children in Gonçalves Dias, a shantytown in Fortaleza, Brazil, that has been recently described in detail.[2] The epidemiology of cryptosporidial infection and presence of lactoferrin in their stools were previously reported.[5] Stools that were available from 18 of these children with only cryptosporidial infection were tested for cytokines, and after having been frozen at −70°C, were retested for lactoferrin. In addition, we also studied nutritional status-matched control children in the same cohort study with no diarrhea for three weeks and no known enteric pathogens.

Information on breast-feeding history, nutritional status, and diarrhea were gathered. Diarrhea was defined as three or

more liquid stools per day lasting at least one day. The children were classified according to having acute (AD) or persistent (PD) diarrhea, defined as diarrhea lasting for < or ≥ 14 days, respectively. *Salmonella, Shigella, Campylobacter,* enterotoxigenic (ETEC), enteropathogenic (EPEC), enteroaggregative (EAggEC), enteroinvasive (EIEC), or enterohemorrhagic (EHEC) *Escherichia coli* (by gene probes], rotavirus, *Giardia, Cyclospora,* or helminths were found using standard methods as previously described.[6,7] Stool specimens were examined for *Cryptosporidium* oocysts by fecal concentrations followed by modified acid-fast and auramine staining.

Fecal dilution. Stool samples were removed from the −70°C freezer and thawed. Small aliquots were diluted in 1:2 (w/v) in phosphate-buffered saline containing 2-amino-4-methylthiazole-5-sulfonyl fluoride, aprotinin, and leupeptin (Sigma, St. Louis, MO). After thorough mixing and centrifugation (10 min at 1,2000 rpm), supernatants were collected and tested for lactoferrin, IL-8, and TNF-α.

Lactoferrin latex agglutination assay. Stool supernatants were tested according to the manufacturer's specifications including appropriate kit controls (LEUKO-TEST; Tech Lab, Blacksburg, VA). Ten microliters of stool supernatant (1:3 dilution) was added to 72.5 μl of diluent yielding a 1:25 dilution. Twenty-five microliters of the sample and 25 μl of sensitized latex (lactoferrin antibody-coated latex beads) were mixed and observed for agglutination after three minutes. Positive and negative controls provided with the test kits were also performed. Agglutination reaction was graded with the unaided eye from 0 (no agglutination) to 3+ (large agglutination with a clear background). For stools positive at a dilution of 1:25, a two-fold serial dilution (1:50 to 1:800) was done until lactoferrin was negative. The highest dilution at which the test result was positive was recorded as the positive titer.

Interleukin-8 and TNF-α assay. IL-8 and TNF-α determinations were performed in stool supernatants using commercially available human IL-8 or TNF-α enzyme immunoassays (Quantikine IL-8 and TNF-α; R&D Systems, Minneapolis, MD and Cytoscreen IL-8; Biosource International, Camarillo, CA). Each test was performed according to the manufacturer's specifications. Briefly, standards and samples were pipetted into wells pre-coated with monoclonal antibodies to IL-8 or TNF-α. Unbound substances were washed off and a substrate solution was added to the wells. The color developed in proportion to the amount of cytokine bound. The color was measured by an enzyme-linked-immunosorbent assay reader. Stool supernatant from a patient with known active inflammatory bowel disease and Caco-2 cell culture supernatant served as positive and negative controls, respectively.

Statistical analysis. For statistical comparison between groups, Fisher's exact test was used. A significant difference was defined as $P < 0.05$.

RESULTS

Cryptosporidiosis in adult volunteers. Among nine *Cryptosporidium* seronegative volunteers, three had diarrhea and oocyst shedding, three had mild or no diarrhea but with oocyst shedding, and three had neither diarrhea nor oocyst shedding. Among six seropositive volunteers, three had diarrhea and oocyst shedding, two had diarrhea but without oocyst shedding, and one had neither diarrhea nor oocyst shedding.

Thirty-six stool specimens from the 15 immunocompetent volunteers were tested for lactoferrin, IL-8, and TNF-α (Table 1). Fifteen stools taken prior to experimental challenge with *C. parvum* oocysts were negative for lactoferrin and IL-8. Of the 21 specimens taken post-challenge, only one had a lactoferrin titer > 1:50 (titer = 1:400) and three had detectable IL-8. The specimen with an elevated level of lactoferrin was from a *Cryptosporidium*-seropositive patient during acute diarrhea. That patient also had an elevated level of IL-8 and oocyst shedding. Lactoferrin, IL-8, and oocysts became undetectable with resolution of symptoms. The other two stool specimens with elevated levels of IL-8 occurred in two individuals who did not develop diarrhea or oocyst shedding; one was from a seropositive volunteer on day 42 post-oocyst ingestion and the other was from a seronegative volunteer on day 9 post-oocyst ingestion. The TNF-α levels in pre-challenge specimens were undetectable or low (highest titer = 10.38 pg/ml). The TNF-α levels in post-challenge specimens were unchanged except for one that had a mildly elevated level of 53 pg/ml. This was from a seropositive volunteer (on day 10 post-oocyst ingestion) who developed diarrhea but did not shed oocysts.

Cryptosporidiosis in children. Of stool specimens screened for enteric pathogens, 73 yielded *Cryptosporidium* oocysts.[5] Nineteen of these 73 specimens were positive only for *Cryptosporidium* oocysts and no other pathogen. These specimens came from 18 children 3–43 months old. Six of these 19 specimens came from children who had height-for-age Z (HAZ) or weight-for-age Z (WAZ) scores of −2 or lower, and eight of 19 had HAZ scores and seven of 19 had WAZ scores of −1 to > −2. Eleven of 19 specimens with cryptosporidiosis came from children who had AD, four who had PD, and four who had no diarrhea. One child had two episodes of cryptosporidiosis: an earlier one associated with diarrhea and malnutrition and another episode, two years later, without diarrhea and malnutrition. The presence of lactoferrin (qualitative de-

TABLE 1

Fecal lactoferrin (LF), interleukin-8 (IL)-8, and tumor necrosis factor-α (TNF)-α in seropositive (+) and seronegative (−) adult volunteers with experimental cryptosporidiosis and with (A) or without (N) diarrhea, and in Brazilian children with acquired cyrptosporidiosis and acute (A), persistent (P), or no (N) diarrhea*

Adults	LF titer	IL-8 (pg/ml)	TNF-α (pg/ml)	Children	IL-8 (pg/ml)	TNF-α (pg/ml)
1 +/A	1:400	1375.6	<10	1 A	14.28	11.79
2 +/A	<1:50	<10	<10	2 A	183.6	ND
3 +/A	<1:50	<10	<10	3 A	252	ND
4 +/A	<1:50	<10	<10	4 A	<10	11.07
5 +/A	<1:50	<10	52.62	5 A	<10	<10
6 −/A	<1:50	<10	10.38	6 A	<10	<10
7 −/A	<1:50	<10	<10	7 A	<10	11.07
8 −/A	<1:50	<10	<10	8 A	<10	<10
9 −/A	<1:50	<10	<10	9 A	<10	<10
10 −/A	<1:50	<10	<10	10 A	<10	10.38
11 −/N	<1:50	<10	<10	11 PO	<10	<10
12 −/N	<1:50	47.55	<10	12 P	ND	ND
13 −/N	<1:50	<10	<10	13 P	ND	ND
14 +/N	<1:50	57.12	<10	14 N	<10	ND
15 −/A	ND	ND	ND	15 N	<10	<10
				16 N	ND	ND
				17 N	ND	ND

scription) was previously reported for the children with cryptosporidial infection.[5] The quantitative lactoferrin levels of the 17 children with only cryptosporidial infection and no other known enteric infections are shown in Figure 1.

Thirteen and 10 specimens from infected children were available for IL-8 and TNF-α assays, respectively (Table 1). Levels of IL-8 were detectable (15–252 pg/ml) in three of 11 children with diarrhea, but not in those without diarrhea. Levels of TNF-α were not elevated (range = 6–12 pg/ml) in any of the 10 children with cryptosporidial infections. Fifteen specimens from children with comparable HAZ and WAZ scores (two with Z scores ≤ –2; $P = 0.257$, five with Z scores > –2 to –1; $P = 0.728$, and eight with Z scores > –1; $P = 0.160$), without diarrhea, and with no enteric pathogens were tested for lactoferrin and IL-8. Lactoferrin levels were elevated only in three of 15 of the control children. Levels of IL-8 were elevated in six (40%) of 15 control children and three (26%) of 13 infected children, but this difference was not significant ($P = 0.435$, by Fisher's exact test). Unfortunately, specimen quantities in the controls did not permit measurement of TNF-α levels.

DISCUSSION

An important diagnostic clue in considering whether diarrhea is an inflammatory or a non-inflammatory process is the examination for fecal leukocytes or lactoferrin. In this study, we used the detection of lactoferrin, a protein found in secondary granules of polymorphonuclear cells, as a marker for fecal leukocytes. Since the fecal lactoferrin test is more sensitive than stool analysis for leukocytes, it may help define mild sub-clinical inflammatory enteritis.[8] We noted that only one of 14 adult volunteers challenged with *Cryptosporidium* oocysts had detectable lactoferrin (Figure 1). In contrast, 12 of 17 specimens from children with only *Cryptosporidium* infection had mild to moderate elevation of fecal lactoferrin. This included 11 of 13 specimens from children with diarrhea, but only one of four asymptomatic infections ($P = 0.05$, by Fisher's exact test). In comparison, only three of 15 HAZ and WAZ score-matched children without diarrhea and no enteric pathogens had elevated levels of lactoferrin ($P = 0.006$, by Fisher's exact test; $P = 0.025$ if the two breast-fed children with increased lactoferrin are excluded). Although the sample size was small, this finding suggests that there may be a mild sub-clinical inflammatory component in cryptosporidiosis in children with diarrhea.

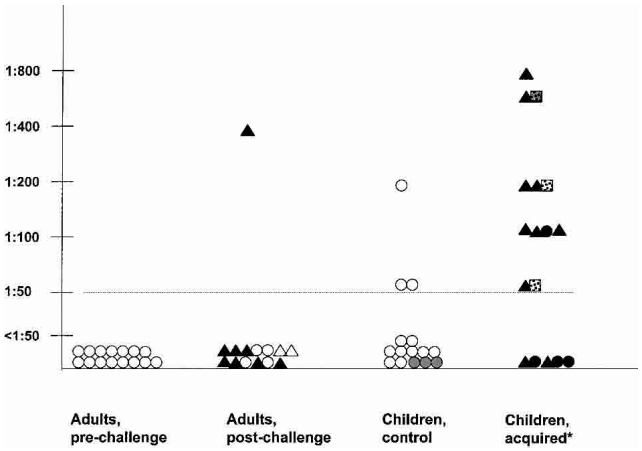

FIGURE 1. Fecal lactoferrin levels in healthy adult volunteers exposed to *Cryptosporidium parvum* and Brazilian children with acquired cryptosporidioisis. Each point represents the highest value for each individual. *Lactoferrin data from 17 children with cryptosporidiosis only of 73 previously reported.[5] $P = 0.006$, by Fisher's exact test, $P = 0.025$ if the two breast-fed children with increased lactoferrin are excluded. ○ = no diarrhea; △ = acute diarrhea; □ = persistent diarrhea; dotted = ooyst shedding; gray = breast-feeding.

It is noteworthy that although only six of 18 children were stunted or wasted (based on the World Heath Organization standard, i.e., HAZ or WAZ ≤ –2, respectively), an additional eight were probably mildly malnourished (Z scores = –1 to > –2), thus affirming previous observations on the association of malnutrition with *Cryptosporidium* infection in developing countries.[1,2] Interestingly, the majority of the children with acute diarrhea (11 AD versus 4 PD) and three with ND had HAZ or WAZ scores ≤ –1 (to –3.1), illustrating that cryptosporidiosis can be associated with malnutrition independent of chronic or persistent diarrhea, as had been shown by others.[9] Inflammatory mediators (e.g., histamine, bradykinin, nitric oxide, platelet-activating factor) and cytokines (e.g., IL-1 and IL-3) are known to be intestinal secretory agonists.[10] Several studies have implied that locally produced cytokines such as IL-1β, TNF-α, and IL-8 act as mediators of mucosal inflammation. Both IL-1β and TNF-α stimulate prostaglandin production *in vitro,* and in experimental colitis the induction of IL-1β precedes the increase of prostaglandin production.[11] Porcine cryptosporidiosis is associated with histologic evidence of inflammation in the lamina propria and IL-1, TNF-α, and prostaglandins have been postulated to have a role in the pathogenesis of cryptosporidiosis.[12] In contrast, expression of TNF-α and IL-1 in adult volunteers did not correlate with enteric symptoms.[13]

This study demonstrated that compared with control and pre-challenge levels of fecal IL-8 in children and human volunteers, respectively, three of 11 children with diarrhea and one of 11 adults who developed diarrhea post-challenge had detectable IL-8. Although this difference was not statistically significant, 40% of the control children were noted to have elevated levels of IL-8 compared with only 23% of the infected children. Whether this implies protection or immunity associated with IL-8 positivity in children is unclear and requires further study. Also, only one adult had mildly elevated levels of fecal TNF-α post-challenge. In contrast, there is evidence of detectable TNF-α mRNA in the majority of jejunal biopsies of healthy volunteers after experimental challenge,[13] and TNF-α and IL-8 mRNA and protein in *C. parvum*-infected human intestinal xenografts in severe combined immunodeficient mice.[14,15] This discrepancy between stool and intestinal tissue cytokine levels may be explained by the greater sensitivity of tissue assays and by the need for repeated assays to detect fecal cytokines. Furthermore, bacteria and proteases in the stool specimens could have destroyed secreted cytokines, resulting in falsely low levels.

There was significantly more inflammation in the children with naturally occurring cryptosporidiosis than seen in the adult volunteers. This may be due to the milder illness noted in volunteer studies. For example, only six of 15 shed oocysts and most had a short duration of illness. It is possible that the difference in the intensity of infection and inflammatory response was due to the presence of other enteric pathogens (e.g., cytomegalovirus or other organisms not commonly seen

in this population) that our screening methodology had missed. Also, although not known in this study, the genotypes of *C. parvum* isolates from the Brazilian children may be distinct from those of the adult volunteers. In a recently published study,[16] the majority of *C. parvum* isolates recovered from infected Peruvian children were of the human genotype (67 of 85 infection episodes).The bovine genotype was reported in only eight cases. Whether inflammatory response is more pronounced or whether there are other factors involved in children in developing areas compared with previously healthy adults warrants further investigation. An inflammatory component of cryptosporidiosis may explain why in malnourished children, the infection is associated more with dehydration, fever, vomiting, prolonged diarrhea, longer hospitalization, and long-term growth and developmental shortfalls.[17,18] More studies on the inflammatory process observed in endemic cryptosporidiosis are needed to shed light on the interrelationship of cryptosporidiosis, malabsorption, and malnutrition especially in children in tropical developing areas.

Received June 11, 2001. Accepted for publication January 31, 2002.

Acknowledgments: We thank Dr. Robert Newman, who reported the original studies of children in Brazil with cryptosporidiosis, for critically reviewing the manuscript. We also thank Yatta Jacob and Chrissie Bradshaw for their technical assistance.

Financial support: This work was supported in part by NIH grant TMRC #2 P50 AI 30639 (UVa Subcontract #00/01.UBF.4), ICIDR grant #UO1 AI26512, USEPA-CR824759 (Volunteer studies), NIH General Clinical Research Center Grant M01-RR-02558 (where volunteers are challenged and monitored), grant RO1 AI-41735, and Fogarty Center International Training and Research in Emerging Infectious Diseases (ITREID) Fellowship Grant 5 D43 TW00909 (Joint funding-FIC/NIAID/NIDR).

Authors' addresses: Cirle S. Alcantara, University of the Philippines-National Institute of Health, Pedro Gil Street, Room 101, Emita, Manila 1000, The Philippines, Telephone/Fax: 63-2-526-4266. Chang-Hun Yang, Division of Gastroenterology and Hepatology, Department of Internal Medicine, University of DongGuk College of Medicine, Kyungju, Korea, Fax: 82-56-1770-8500. Theodore S. Steiner, Infectious Diseases Division, University of British Columbia, Vancouver, British Columbia V5Z 3J5, Canada, Fax: 604-875-4013. Leah J. Barrett and Richard L. Guerrant, Division of Geographic and International Medicine, University of Virginia School of Medicine, Box 801379, Charlottesville VA 22908, Telephone: 434-924-5242, Fax: 434-977-5323, E-mail: rlg9a@virginia.edu. Aldo A. M. Lima, Clinical Research Unit, Federal University of Ceará, Fortaleza, Brazil, Fax: 55-85-281-5212. Cynthia L. Chappell, Center for Infectious Disease, University of Texas School of Public Health, Houston, TX 77030, Fax: 713-500-9364. Pablo C. Okhuysen, Division of Infectious Diseases, University of Texas-Houston Medical School, Houston, TX 77030, Fax: 713-500-5495. A. Clinton White, Jr., Infectious Diseases Section, Department of Medicine, Baylor College of Medicine, Houston, TX 7730, Fax: 713-798-6802.

REFERENCES

1. Sallon S, Deckelbaum RJ, Schmid I, Harlap S, Baras M, Spira DT, 1988. *Cryptosporidium,* malnutrition, and chronic diarrhea in children. *Am J Dis Child 142:* 312–315.
2. Lima AA, Moore SR, Barboza MS Jr, Soares AM, Schleupner MA, Newman RD, Sears CL, Nataro JP, Fedorko DP, Wuhib T, Schorling JB, Guerrant RL, 2000. Persistent diarrhea signals a critical period of increased diarrhea burdens and nutritional shortfalls: a prospective cohort study among children in northeastern Brazil. *J Infect Dis 181:* 1643–1651.
3. Sears CL, Guerrant RL, 1994. Cryptosporiodiosis: the complexity of intestinal pathophysiology. *Gastroenterology 106:* 252–254.
4. DuPont HL, Chappell CL, Sterling CR, Okhuysen PC, Rose JB, Jakubowski W, 1995. The infectivity of *Cryptosporidium parvum* in healthy volunteers. *N Engl J Med 332:* 855–859.
5. Newman RD, Sears CL, Moore SR, Nataro JP, Wuhib T, Agnew DA, Guerrant RL, Lima AAM, 1999. Longitudinal study of *Cryptosporidium* infection in children in northeastern Brazil. *J Infect Dis 180:* 167–175.
6. Fang G, Lima AAM, Martins CC, Nataro JP, Guerrant RL, 1995. Etiology and epidemiology of persistent diarrhea in northeastern Brazil: a hospital-based prospective case control study. *J Pediatr Gastroenterol Nutr 21:* 137–144.
7. Schorling JB, Wanke CA, Schorling SK, McAuliffe JF, de Souza MA, Guerrant RL, 1990. A prospective study of persistent diarrhea among children in an urban Brazilian slum. *Am J Epidemiol 132:* 144–156.
8. Guerrant RL, Araujo V, Soares E, Kotloff K, Lima AA, Cooper WH, Lee AG, 1992. Measurement of fecal lactoferrin as a marker of fecal leukocytes (see comments). *J Clin Microbiol 30:* 1238–1242.
9. Checkley W, Gilman RH, Epstein LD, Suarez M, Diaz JF, Cabrera L, Black RE, Sterling CR, 1997. Asymptomatic and symptomatic cryptosporidiosis: their acute effect on weight gain in Peruvian children. *Am J Epidemiol 145:* 156–163.
10. Ciancio MJ, Chang EB, 1992. Epithelial secretory response to inflammation. *Ann NY Acad Sci 664:* 210–221.
11. Elias JA, Gustilo K, Baeder W, Freundlich B, 1900. Synergistic stimulation of fibroblast prostaglandin production by recombinant interleukin 1 and tumor necrosis factor. *J Immunol 138:* 3812–3816.
12. Robinson P, Okhuysen PC, Chappell CL, Lewis DE, Shahab I, Janecki A, White AC Jr, 2001. Expression of tumor necrosis factor alpha and interleukin 1 beta in jejuna of volunteers after experimental challenge with *Cryptosporidium parvum* correlates with exposure but not with symptoms. *Infect Immun 69:* 1172–1174.
13. Argenzio RA, Lecce J, Powell DW, 1993. Prostanoids inhibit intestinal NaCl absorption in experimental porcine cryptosporidiosis. *Gastroenterology 104:* 440–447.
14. Seydel KB, Zhang T, Champion GA, Fichtenbaum C, Swanson PE, Tzipori S, Griffiths JK, Stanley SL Jr, 1998. *Cryptosporidium parvum* infection of human intestinal xenografts in SCID mice induces production of human tumor necrosis factor alpha and interleukin-8. *Infect Immun 66:* 2379–2382.
15. Laurent F, Eckmann L, Savidge TC, Morgan G, Theodos C, Naciri M, Kagnoff MF, 1997. *Cryptosporidium parvum* infection of human intestinal epithelial cells induces the polarized secretion of C-X-C chemokines. *Infect Immun 65:* 5067–5073.
16. Xiao L, Bern C, Limor J, Sulaiman I, Roberts J, Checkley W, Cabrera L, Gilman RH, Lal AA, 2001. Identification of 5 types of *Cryptosporidium* parasites in children in Lima, Peru. *J Infect Dis 183:* 492–497.
17. MacFarlane DE, Horner-Bryce J, 1987. Cryptosporidiosis in wellnourished and malnourished children. *Acta Paediatr Scand 76:* 474–477.
18. Guerrant DI, Moore SR, Lima AA, Patrick PD, Schorling JB, Guerrant RL, 1999. Association of early childhood diarrhea and cryptosporidiosis with impaired physical fitness and cognitive function four-seven years later in a poor urban community in northeast Brazil. *Am J Trop Med Hyg 61:* 707–713.