

## EXTENDED INTERHUMAN TRANSMISSION OF MONKEYPOX IN A HOSPITAL COMMUNITY IN THE REPUBLIC OF THE CONGO, 2003

LYNNE A. LEARNED,† MARY G. REYNOLDS,†\* DEMOLE WASSA WASSA, YU LI, VICTORIA A. OLSON, KEVIN KAREM, LINDA L. STEMPORE, ZACH H. BRADEN, RICHARD KLINE, ANNA LIKOS, FRANÇOIS LIBAMA, HENRI MOUDZEO, JEAN DANIEL BOLANDA, PAUL TARANGONIA, PAUL BOUMANDOKI, PIERRE FORMENTY, JOSEPH M. HARVEY, AND INGER K. DAMON

*School of Medicine and Biomedical Sciences, State University of New York, Buffalo, New York; Division of Viral and Rickettsial Diseases, Centers for Disease Control and Prevention, Atlanta, Georgia; Ministry of Health and Populations, Impfondo, Republic of Congo; Ministry of Health and Populations, Brazzaville, Republic of Congo; Alert and Response Operations Office, World Health Organization, Geneva, Switzerland; Global Outreach Mission, Pioneer Christian Hospital, Impfondo, Republic of Congo*

**Abstract.** This report describes the first reported outbreak of human monkeypox in the Republic of Congo. Eleven confirmed and probable monkeypox cases were observed during this outbreak, all were less than 18 years old, and most resided on the grounds of the Government Hospital in Impfondo. Molecular, virologic, and serologic, and diagnostic assays were used to detect evidence of monkeypox (or orthopox) virus infection in individuals with striking dermatologic and other clinical manifestations. The majority of cases in this outbreak experienced significant, symptomatic illnesses; there was one death, possibly involving secondary complications, and one instance of profound sequelae. Up to six sequential transmissions of monkeypox virus from person to person are hypothesized to have occurred, making this the longest uninterrupted chain of human monkeypox fully documented to date. The pattern of sustained human-to-human transmission observed during this outbreak may influence our current perception of the capacity for this zoonotic virus to adapt to humans.

### INTRODUCTION

Monkeypox virus was first recognized as a pathogen of humans during the early 1970s in west and central Africa, during a time of intensification of smallpox eradication efforts.<sup>1,2</sup> Since that time, sporadic disease has been observed independently in multiple countries in forested regions of west and central Africa (e.g., Democratic Republic of Congo, Central African Republic, Gabon, Liberia, Sierra Leone<sup>3–7</sup>). The true range of human endemic disease has yet to be determined; however, it is likely to coincide with the natural range of the zoonotic reservoir species, the identity of which remains largely speculative although several species of rodents have been proposed as candidates.<sup>8–10</sup>

In May–June 2003, human infections with monkeypox virus were reported in the United States following importation of virus infected animals that had been collected in the wild from the west African nation of Ghana.<sup>11</sup> This event represents the sole instance whereby monkeypox virus exported from virus-endemic regions has resulted in human infections. The manifestations of human illness seen during the U.S. outbreak were relatively mild (with exceptions<sup>12–14</sup>), although the individuals affected were on average older than those generally observed with severe disease in African outbreaks. Notably, no human-to-human virus transmission was reported during the 2003 US outbreak, and there were no human deaths<sup>11</sup> (Cono J, unpublished data).

In pronounced contrast to this, a nearly simultaneous focus of human monkeypox was identified in the town of Impfondo in the remote heavily forested district of Likouala in the Republic of Congo. This outbreak likely began in April 2003, and ended with recovery of the last case in mid-July. Most of the reported infections occurred in children < 12 years of age,

many of whom were hospitalized with serious illnesses. Human-to-human transmission was a prominent feature of this outbreak, with seven generations (six sequential passages) of serial transmission hypothesized to have occurred.

### MATERIALS AND METHODS

**Location and description of the outbreak.** On April 15, 2003, the Chief of Medicine and Pediatrics at the Government Hospital in Impfondo examined an 11-year-old boy who resided near the rural town of Dongou (44.2 km from Impfondo) who was in Impfondo visiting relatives (Figure 1). The boy had fever and pox-like lesions, but was not admitted to the hospital. Approximately two weeks later, a second child with a similar illness was evaluated by the same physician. This child lived at the Impfondo residence where the first ill child stayed during his illness (approximately 0.2 km from the Government Hospital). During the subsequent three weeks, five additional children, all with shared contact with each other, were admitted to the hospital with febrile illness accompanied by vesiculo-pustular rash, or with febrile prodromes that progressed to include vesiculo-pustular rash.

On June 11, alarmed by the severity and number of the recent cases, and convinced that the illnesses were not due to varicella, the Chief of Medicine and Pediatrics at the Government Hospital in Impfondo sent photographs depicting the rashes of two cases to colleagues in Brazzaville. A resident American tropical diseases specialist (JMH) was invited to assist in diagnosis and infection control because the illness was by that time perceived to be communicable within the hospital setting. On June 19, the U.S. embassy and the Centers for Disease Control and Prevention (CDC) in the United States were notified of the existence of the focus of variola-like cases in Impfondo. The CDC was requested to assist in identifying the etiology of the infections. Blood specimens and lesion materials were collected from four hospitalized children on June 20 and sent to CDC. Authorities were notified on June 25 by the poxvirus laboratories at CDC that

† These authors contributed equally to this work.

\* Address correspondence to Dr. Mary G. Reynolds, Division of Viral and Rickettsial Diseases, Centers for Disease Control and Prevention, 1600 Clifton Road NE, Atlanta, GA 30333. E-mail: nzzr6@cdc.gov

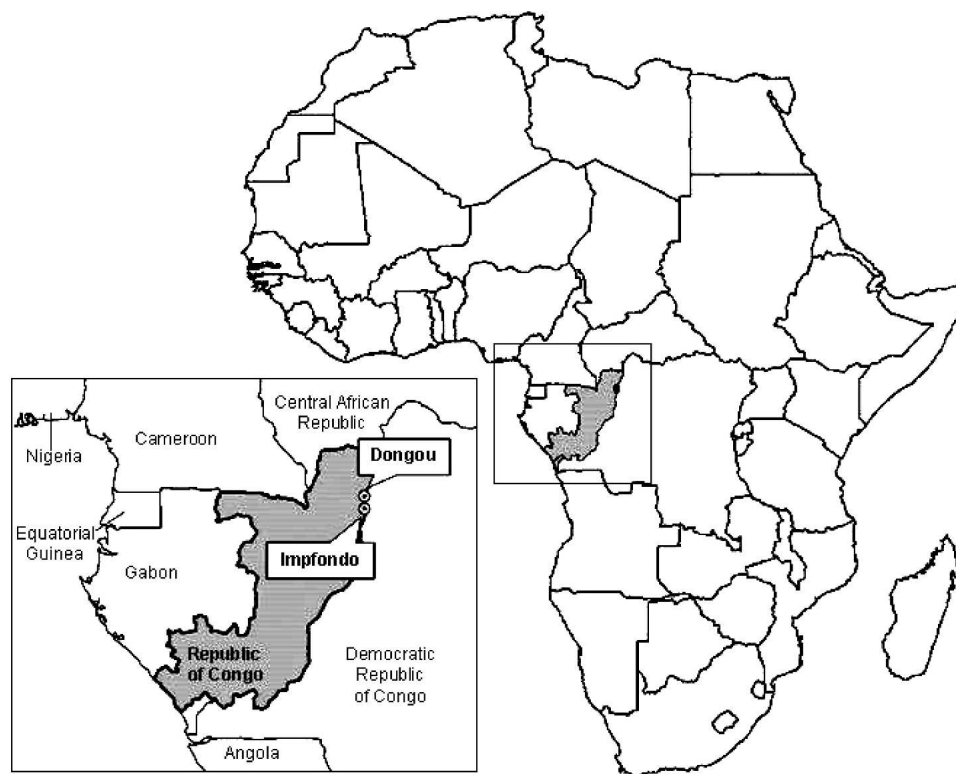

FIGURE 1. Location of human monkeypox cases in the Republic of Congo, 2003.

monkeypox virus DNA signatures were present in the clinical specimens, at which time the Ministry of Health and Population of the Republic of Congo launched an official investigation of the outbreak. Illness onset of the final recorded case in Impfondo occurred on June 23, 2003.

**Epidemiologic and clinical information.** Clinical and epidemiologic information pertaining to cases was collected using patient and family interviews, physician notes, and hospital records as data sources.

**Laboratory analysis of clinical specimens.** Molecular, virologic, and serologic assays were used for diagnosis of monkeypox and/or orthopox virus infection in symptomatic individuals. Polymerase chain reaction (PCR)-based molecular assays were performed using DNA prepared from lesions, swabs, smears, and EDTA-whole blood specimens; in some cases whole, unpreserved blood was used if no other samples were available. Specimens positive for monkeypox were those that yielded positive results in at least two independent PCR tests (targeting different loci), including one that discriminates monkeypox-specific DNA signatures from those of other orthopox viruses. Assays designed to detect generic-level and species-specific DNA signatures, as well as virus culture procedures, have been described elsewhere.<sup>13,15,16</sup>

Serologic testing alone was used to define disease status for individuals who had a recent compatible illness, but no active lesions at the time of specimen collection. Enzyme-linked immunosorbent assays were used for detection of orthopox-specific IgG or IgM antibodies from patient sera. The presence of elevated levels of orthopox reactive IgG antibodies in sera can indicate either monkeypox infection, or a previous vaccination against smallpox. The presence of elevated IgM titers between, at minimum, days 7–56 post-rash onset in per-

sons with compatible clinical and epidemiologic characteristics is considered an indication of probable case status (Appendix 1).

**Epidemiologic case classifications.** Cases were classified epidemiologically as confirmed, probable, or suspect based on a standard case definition (Appendix 1). This definition was modified from that used during the 2003 outbreak in the United States (<http://www.cdc.gov/ncidod/monkeypox/casedefinition.htm>).

## RESULTS

**Person-to-person transmission.** Case 0 was unavailable for an interview at the time of the investigation; therefore, the nature of his potential exposures to monkeypox virus is not known. The timing of illness onset of the Impfondo index case (case 1, Table 1) suggests that monkeypox virus was likely imported with the visit of case 0 (Figure 2). It was learned upon investigation that case 1 did own a pet monkey (*Cercopithecus* sp.). On visual inspection in June, the animal appeared to be in good health, and the family could not recall its having been ill within the previous four months. No other potential wild animal exposures were reported for this child, or for the other patients described below. The approximate case interval (number of days between fever onsets) between cases 0 and 1 is consistent with previous descriptions of person-to-person transmission of monkeypox.<sup>17</sup>

All subsequent confirmed, probable, and suspect cases in the outbreak had epidemiologic linkage to the Government Hospital in Impfondo. Cases 3a, 4, 5, and 5a (siblings) resided on the grounds of the hospital, where their father worked as a physician's assistant for medicine and pediatrics. Case 2, a 16-year-old mother, was a frequent visitor to their household,

TABLE 1

Exposure histories, illness characteristics, and outcomes for confirmed, probable, and suspect cases of monkeypox, Impfondo, Republic of Congo, 2003\*

Case no.	Case class	Sex	Age (years)	Onset (2003)†	Lesion no.	Signs and symptoms	Outcomes/sequelae	Exposure
0	Probable	M	~11	~April 15‡	NR	NR	Not hospitalized	Cousin of case 1; was a visitor at home of case 1 in Impfondo while symptomatic
1	Probable	M	~11	~April 28‡	0–50	NR	Not hospitalized; hypopigmented lesion sites > 6 weeks post-illness onset	Contact with case 0 during illness; cousin of cases 3a, 4, 5, and 5a; family friend of cases 2, 3, and 6
2	Probable	F	16	May 8	0–5	Distress on admission	Hypopigmented lesion sites > 6 weeks post-illness onset	Frequently stayed on hospital compound with family of cases 3a, 4, 5, and 5a; daughter of case 6, mother of case 3
3	Confirmed	M	< 1	May 18	> 200	Malaise, irritability, coryza	Hypopigmented lesion sites > 6 weeks post-illness onset	Child of case 2, grandson of case 6
3a	Probable	M	5	May 18	> 200	Malaise, listlessness, distress on admission	Discharged without complications	Child of hospital worker§, lives on hospital compound; sibling of cases 4, 5, and 5a
4	Probable	M	10	May 28	0–50	NR	Discharged without complications	Child of hospital worker§, lives on hospital compound; sibling of cases 3a, 5, and 5a
4a	Probable	F	10	May 30	NR	Lower back pain, distress on admission, spiking fevers	Admitted with presumed UTI; exploratory surgery; died June 7 with perineal infection	Child of hospital worker¶, lived on hospital compound; sister of case 5b
5	Confirmed	F	8	June 5	> 200	Lethargy, malaise, distress on admission	Severe viral conjunctivitis of left eye, erythematous sclera, opaque pupil; persistent listlessness and fatigue; hypopigmented lesions > 6 weeks post-illness onset	Child of hospital worker§, lives on hospital compound; sibling of cases 3a, 4, and 5a; shared hospital room with case 3
5a	Probable	M	3	June 5	0–50	NR	Not hospitalized; illness mild	Child of hospital worker§, lives on hospital compound; sibling of 3a, 4, and 5
5b	Confirmed	M	4	June 10	50–100	Anterior cervical lymphadenopathy, irritability, lethargy, coryza, cough	Discharged without complications	Child of hospital worker¶, lives on hospital compound; brother of case 4a
6	Suspect	F	> 30	June 22	No rash	Malaise, headache	NR	Mother of case 2; provided nursing care to cases 2 and 3
6a	Probable	M	17	June 23	0–50	Anterior cervical lymphadenopathy	Discharged without complications	Hospitalized with presumed malaria on June 17; re-admitted with rash and fever on June 26

\* NR = not recorded; UTI = urinary tract infection.

† Date of fever onset.

‡ Onset dates are estimated based on physician recollection.

§ Father of cases 3a, 4, 5, and 5a is a physician's assistant at the Government hospital in Impfondo in charge of medicine and pediatrics.

¶ Father of cases 4a and 5b is a nurse at the Government hospital in Impfondo.

as was case 1, who is described as a cousin and who lived nearby. Also residents in the hospital compound were cases 4a and 5b (siblings) whose father was a nurse at that facility. Neither of the adult staff members who were parents of cases had illness during the period of the outbreak, and both reported having been vaccinated against smallpox.

Case 3, the infant son of case 2, stayed with his mother

throughout her hospitalization. Both received nursing care from the infant's grandmother, case 6 (suspect). Twenty-two days into the hospitalization of case 3, another sick child, case 5, was moved into the same room; two weeks later, case 6 developed fever, headache, and malaise. Case 6 never developed a rash, and laboratory testing for evidence of monkeypox infection, or recent orthopoxvirus exposure, was incon-

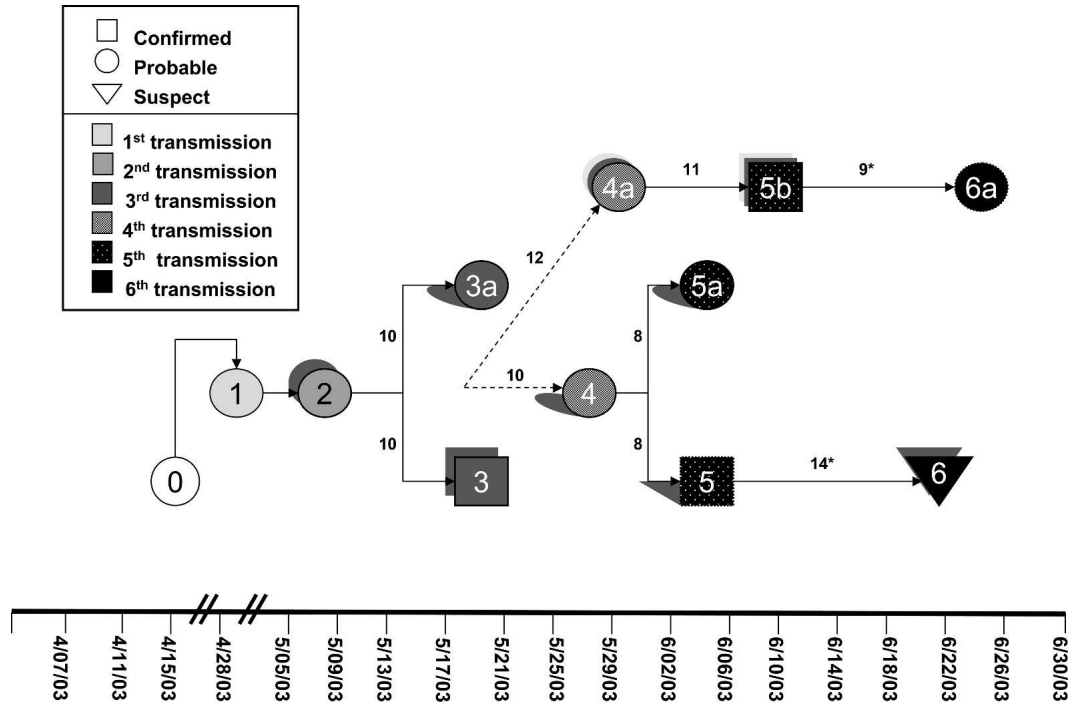


FIGURE 2. Pattern of virus transmission hypothesized to have occurred during the outbreak of human monkeypox in the Republic of Congo, 2003. Cases are arranged according to illness onset dates. Solid arrows indicate probable lines of person-to-person transmission and dashed arrows depict undetermined transmission events. Numbers in proximity to arrows refer to the number of days between case onsets (case intervals); approximate case intervals are denoted with asterisks. Cases belonging to the same immediate family are rendered with common shadowing styles.

clusive. Case 6 was observed to have a smallpox vaccination scar.

Two patients were initially admitted to the hospital with presumptive diagnoses of malaria (5b and 6a). Case 5b may have been incubating monkeypox when hospitalized for suspected malaria. Upon treatment, his first fever abated only to recrudescence on day 7 post-admission. He developed vesiculopustular lesions on the palms of his hands, soles of his feet, and trunk three days later. Case 6a was treated and discharged for malaria prior to being readmitted nine days later with the above characteristic signs of monkeypox. He reported no other exposures to monkeypox and is likely to have acquired his infection during his hospitalization for malaria.

Active surveillance among exposed hospital staff was not formally pursued. However, none of the adult health care workers at the Government Hospital in Impfondo reported experiencing symptoms of febrile illness either during, or up to three weeks after the time that monkeypox patients were hospitalized. Household census information was insufficient to allow for reliable calculation of secondary attack rates.

**Transmission generations.** Case exposure histories, observed case intervals and the absence of other potential exposure sources all support the hypothesis that at least seven discrete virus generations (six serial transmissions) occurred during this outbreak. This constitutes longest chain of human-to-human transmission of monkeypox virus yet documented. Why this chain was apparently truncated at six generations remains undetermined, but infection control recommendations made by the Ministry of Health coincident with the timing of symptom onset of the final patient (case 6) may have influenced this outcome.

A previous report from a large outbreak of monkeypox

that occurred in the Katak-Kombe health zone of the Democratic Republic of Congo in 1996 alludes to a cascade of transmission that affected eight members of a single clan, but the architecture of this cluster was not described. Additionally, case identification during that outbreak was complicated by concurrent transmission of varicella virus (the agent of chickenpox) in affected communities.<sup>7,18</sup>

The case intervals range from 8 to 12 days, with a median of 10 (mean = 9.9, SD = 1.5, n = 7). The approximate elapsed time interval from the onset of illness of the first to the final case is 69 days, which is within the range of biologic plausibility for monkeypox.

**Case characteristics.** There were 11 individuals in this outbreak who were classified as confirmed or probable cases of monkeypox (Appendix 1). Eight of these 11 cases (73%) were male, and all were < 8 years (median = 8 years of age, n = 9). None had been vaccinated against smallpox (Table 1).

**Clinical characteristics of cases.** All but three of the 11 cases in this outbreak were hospitalized. Among the nine cases for whom information was available, the progression of the illness was similar, with a 2–3-day febrile prodrome followed by skin eruption (Figure 3A). Rash burden tended to be higher in younger children, but the association between rash intensity and age was not significant. Disease severity was not associated with generation of transmission because the final confirmed and probable cases were not markedly less ill (nor more ill) than the initial cases.

One case was initially admitted with fever and lower back pain and given a preliminary diagnosis of urinary tract or renal infection. When her condition worsened, exploratory surgery was performed. She died eight days after admission with perineal infection, fever, and generalized vesiculo-

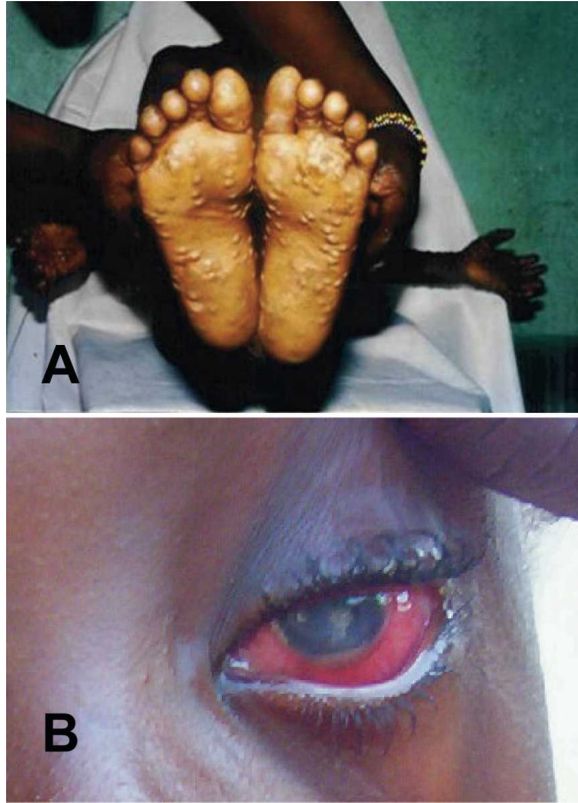

FIGURE 3. **A**, Child with pustular-stage rash consisting of ~200, 3–5-cm, flaccid, vesicular lesions, all at a similar stage of development, with classic centrifugal distribution (lesions located preferentially on the palms of the hands, the soles of the feet, and on the scalp and face). Fewer lesions were also noted on his neck, trunk, perineum, and all four limbs. **B**, Child with viral conjunctivitis causing intensely erythematous sclera and corneal opacities obscuring the pupil. This figure appears in color at [www.ajtmh.org](http://www.ajtmh.org).

pustular rash. Her cause of death was undetermined since she died with both acute monkeypox infection and a post-operative infection. A second child was observed six weeks post-illness onset with a severe sustained viral conjunctivitis of the left eye, with extensive damage. At evaluation, she was noted to have corneal opacities obscuring her pupil and an erythematous sclera (Figure 3B). Several children retained hypopigmented areas where lesions had occurred up to eight weeks from illness onset. The rash and fever in the infant child abated, but he never regained full health and died approximately six months later, reportedly due to some form of hemolytic anemia.

**Laboratory parameters.** Preservative-containing blood specimens were obtained from a subset of case patients. No blood specimens sent to CDC yielded live virus, but EDTA-whole blood from three of five patients examined (all of whom had severe rash burdens) yielded evidence of virus-specific DNA signatures (Table 2). Two additional case-patient blood samples yielded no evidence of viral DNA.

Elevated levels of orthopox-reactive IgG and IgM antibodies were observed for eight cases, all of whom had illness clinically compatible with monkeypox and valid epidemiologic exposures. Two individuals did not exhibit elevated levels of IgM antibody to orthopox virus; however, serologic specimens from both individuals were collected outside the

optimal timeframe for detection (Karem K, unpublished data).

**Febrile rash illness not attributable to monkeypox.** Three individuals 2, 7, and 21 years of age came to the Government Hospital in Impfondo with febrile rash illnesses (the two younger individuals came on July 7, 2003 and the adult came on July 19). All three were residents of Impfondo; none had a defined epidemiologic relationship with any known human monkeypox case. All three complained of (current or prior) fever, and pruritic, vesicular-pustular rash, although none had defined febrile prodromes prior to rash development. On examination, all had lymphadenopathy and cough. In addition, the youngest patient had pronounced rhinorrhea and dyspnea. The eldest patient, whose infant daughter had experienced a similar illness days earlier, had both rhinorrhea and headache on presentation. All three patients were sent home after evaluation with diagnoses of varicella.

Laboratory tests performed on EDTA-whole blood specimens collected from all three individuals were negative for monkeypox virus by PCR and virus culture, as was a rash lesion specimen collected from the 21-year old person. Serologic specimens collected from the 2- and 7-year-old children (on days 14 and 20 post-rash onset, respectively) were also negative for orthopox virus-reactive immunoglobulins. None of these individuals were considered to have had monkeypox virus infection.

## DISCUSSION

This report describes the first outbreak of human monkeypox to occur in the Republic of Congo. A hospital-based outbreak, even in a region endemic for monkeypox, raises concern for several reasons, including health care worker safety and potentially diminished local access to health care. No health care workers were observed to have become ill during this outbreak, but there was hospital-associated transmission occurring either within the confines of the hospital itself or on the hospital grounds, where neighborhood children and children of hospital workers socialized together.

Vaccination for smallpox anywhere from 3 to 19 years prior to exposure has been demonstrated to be up to 85% effective in protecting against infection with monkeypox virus.<sup>18</sup> Thus, it is not unusual that health care workers were spared during this outbreak. Routine smallpox vaccinations did not cease in most regions of Africa until 1980. Therefore, individuals born before that date would likely have had an opportunity to be vaccinated. The chief of Medicine and Pediatrics at the Government Hospital and both of the health care workers whose children were case patients had a history of smallpox vaccination. This notwithstanding, doctors and nurses at the Government Hospital in Impfondo had little to no access to personal protective equipment (examination gloves, gowns, masks, respirators, etc.), or supplies for disinfection or hand washing. Although today's hospital worker may retain the benefit of vaccine-derived immunologic protection, it is conceivable that health care workers will become increasingly vulnerable as more unvaccinated individuals come of age and join the professional workforce. Thus, there exists the future potential for larger and more frequent hospital-associated monkeypox outbreaks. Such occurrences could have devas-

TABLE 2  
Results of diagnostic assays performed on clinical specimens\*

Case no.	Serology			Molecular and virologic assays			
	OPX reactive IgG†	OPX reactive IgM†	Days from rash onset to serum collection	OPX/MPX PCR‡	Virus culture	Clinical specimen	Days from rash onset to specimen collection
1	Pos	Neg	> 53	ND	ND	NA	NA
2	Pos	Pos	41	Neg	Neg	Blood	41
				Neg	Neg	Blood	43
3	Pos	Pos	33	Pos	ND	Blood	33
3a	Pos	Pos	27	Neg	Neg	Blood	27
4	Pos	Pos	24	ND	ND	NA	NA
5	Pos	Pos	12	Pos	Pos	Lesion swab	12
				Pos	Neg	Blood	12
				Pos	ND	Lesion (scab)	15
				Pos	Pos	Lesion (skin)	15
5a	Pos	Pos	15	Neg	Neg	Blood	15
5b	Pos	Pos	8	Pos	Neg	Blood	8
				Neg	Neg	Smear	8
				Pos	Neg	Lesion (fluid)	11
				Pos	Neg	Lesion (fluid)	11
6	Pos	Neg	(1)§	Neg	Neg	Blood	(1)§
6a	Pos	Pos	28	Neg	Neg	Blood	28

\* ND = not done; NA = not applicable.

† Positive (Pos) indicates a specimen optical density (OD) reading > 3 SD above the mean OD of the negative (Neg) controls by an enzyme-linked immunosorbent assay. Detection of elevated orthopox-specific IgM allowed the identification of five additional cases (probable) that would otherwise have remained suspect.

‡ Positive indicates specimen was positive for orthopox (OPX) virus DNA signatures in at least two independent polymerase chain reaction (PCR) tests (evaluating different loci), one of which must allow for discrimination of monkeypox-specific DNA signatures from other orthopox virus signatures. Detection limits for real-time PCR tests used during this study are estimated as ~20 fg (corresponds to 100 genome copies) of monkeypox DNA per reaction using purified monkeypox virus DNA.

§ Specimens were collected on the first day of fever. The individual did not develop a rash.

tating impacts on local health care infrastructure, underscoring the need to explore vaccination strategies for at risk populations. There are currently no recognized guidelines for the use of smallpox vaccines (vaccinia) for the prevention or control of monkeypox in communities with a high prevalence of human immunodeficiency virus (HIV) because of concerns over the potential for severe adverse events.

The existence of a stable zoonotic reservoir source for the virus around the hospital compound in Impfondo cannot be entirely discounted, but several observations support a hypothesis of sustained chain of human-to-human transmission. These include the clustering of successive cases within families, the uniformity of case intervals, and patient exposure histories that emphasized extensive human-to-human contact. However, this is not the first documented hospital-based outbreak of monkeypox. Human-to-human transmission of monkeypox virus among children in a hospital setting has been reported,<sup>6</sup> but in that instance the chain of transmission was truncated at the fourth generation, and the observed case intervals were relatively long (median = 17.5 days). Here, in contrast, we hypothesize the existence of at least six serial transmissions of virus with relatively short (median = 10 days), uniform case intervals, which is suggestive of either intense exposures or highly efficient transmission.

The suggestion of efficient transmission during this outbreak is significant because monkeypox virus has often been considered to be of only nominal importance as a human pathogen, due principally to its perceived limited capacity for human-to-human spread. This notion received support from stochastic models developed by Jezek and others<sup>19</sup> and elaborated by Fine and others,<sup>20</sup> which simulated outcomes of monkeypox outbreaks under varied epidemiologic parameters (i.e., vaccination coverage, secondary attack rates). These models projected that even under highly permissive scenarios, assuming maximum estimates for secondary attack

rates (~4% aggregated) and 0% vaccine-derived immunity within the population, less than 10% of the predicted virus introductions would lead to transmission chains greater than five generations, and ultimately none would spur community-wide epidemics.

Using these models as a guide, the existence of the extended chain of monkeypox transmission described in this report (in theory a rare event) would imply that there is a substantial, unappreciated background incidence of monkeypox in the region. An alternative interpretation might be that these models, which accentuate the lack of monkeypox virus transmissibility among humans, no longer provide an accurate representation of the epidemic potential of the virus. This may be due to changes within human or zoonotic populations (e.g., the spread of HIV, altered access to health care facilities, altered population age structure of the population, ecological disturbance, etc.)

More recently, Antia and others<sup>21</sup> have used epidemiologic models simulating outcomes of zoonotic virus introductions into human communities to suggest that when the perceived basic reproductive rate ( $R_0$ ) of a virus in human populations is too low to suggest epidemic potential ( $R_0 < 1$ ), even minor, incremental increases in the contact frequency, or in the efficiency of person-to-person transmission (which could be behaviorally or ecologically driven, or a consequence of genetic changes in the virus), can substantially enhance opportunities for selection of more highly adapted mutants. Stated simply, more introductions and longer, more complex transmission chains can increase the probability for emergence of human-adapted viruses capable of efficient spread. This outbreak suggests the potential for both.

This outbreak was ultimately extinguished after six serial transmissions, but both the short case intervals and the extended chain of transmission seen in this outbreak serve to reinforce the idea that the potential for monkeypox virus to

emerge as a significant human pathogen, may indeed be greater than previously appreciated. This outbreak occurred in a remote, underserved part of Africa, in all respects a prime location for disease emergence. That the origin of this outbreak was not definitively identified, and may have been associated with ongoing transmission in two nearby towns, argues for increased efforts aimed at disease surveillance and definitive case identification to better understand the overall burden of disease and to identify sources for virus introduction into communities. Additionally, the potential vulnerability of health care workers (and their children) in Impfondo and other monkeypox-endemic areas should stimulate consideration of new strategies for vaccination, possibly involving replication deficient, or less reactogenic vaccines such as modified vaccinia Ankara,<sup>22</sup> which have the potential to circumvent problems associated with risk factors (including HIV) for adverse events from the current smallpox vaccine.

Received December 30, 2004. Accepted for publication February 22, 2005.

**Acknowledgments:** We thank the World Health Organization Regional Office for Africa in Brazzaville, the U.S. Department of State, and the Ministry of Health and Populations of the Republic of Congo for their assistance during this outbreak. For more information on monkeypox, please visit [www.cdc.gov/ncidod/monkeypox](http://www.cdc.gov/ncidod/monkeypox).

**Note:** The case definition for human monkeypox in the Republic of Congo appears online at [www.ajtmh.org](http://www.ajtmh.org).

**Authors' addresses:** Lynne A. Learned, School of Medicine and Biomedical Sciences, State University of New York, Buffalo, NY 14214-3013. Mary G. Reynolds, Yu Li, Victoria A. Olson, Kevin Karem, Linda L. Stempora, Zach H. Braden, Richard Kline, Anna Likos, and Inger K. Damon, Division of Viral and Rickettsial Diseases, Centers for Disease Control and Prevention, 1600 Clifton Road NE, Mailstop G-18, Atlanta, GA 30333, Telephone: 404-639-2878, Fax: 404-639-3111, E-mail: [nzr6@cdc.gov](mailto:nzr6@cdc.gov). Demole Wasswa Wasswa, Ministry of Health and Populations, Impfondo, Republic of Congo. François Libama, Henri Moudzeo, Jean Daniel Bolanda, Paul Tarangonia, and Paul Boumandoki, Ministry of Health and Populations, Brazzaville, Republic of Congo. Pierre Formenty, Alert and Response Operations Office, World Health Organization, Geneva, Switzerland. Joseph M. Harvey, Global Outreach Mission, Pioneer Christian Hospital, Impfondo, Republic of Congo.

## REFERENCES

- Marennikova SS, Seluhina EM, Mal'ceva NN, Cimiskjan KL, Macevic GR, 1972. Isolation and properties of the causal agent of a new variola-like disease (monkeypox) in man. *Bull World Health Organ* 46: 599–611.
- Ladnyj ID, Ziegler P, Kima E, 1972. A human infection caused by monkeypox virus in Basankusu Territory, Democratic Republic of the Congo. *Bull World Health Organ* 46: 593–597.
- Foster SO, Brink EW, Hutchins DL, Pifer JM, Lourie B, Moser CR, 1972. Human monkeypox. *Bull World Health Organ* 46: 569–576.
- Lourie B, Bingham PG, Evans HH, Foster SO, Nakano JH, Herrmann KL, 1972. Human infection with monkeypox virus: laboratory investigation of six cases in West Africa. *Bull World Health Organ* 46: 633–639.
- Breman JG, Kalisa R, Steniowski MV, Zanotto E, Gromyko AI, Arita I, 1980. Human monkeypox, 1970-79. *Bull World Health Organ* 58: 165–182.
- Jezeck Z, Arita I, Mutombo M, Dunn C, Nakano JH, Szczeniowski M, 1986. Four generations of probable person-to-person transmission of human monkeypox. *Am J Epidemiol* 123: 1004–1012.
- Hutin YJ, Williams RJ, Malfait P, Pebody R, Loparev VN, Ropp SL, 2001. Outbreak of human monkeypox, Democratic Republic of Congo, 1996 to 1997. *Emerg Infect Dis* 7: 434–438.
- Khodakevich L, Szczeniowski M, Manbu mD, Jezeck Z, Marennikova S, Nakano J, 1987. The role of squirrels in sustaining monkeypox virus transmission. *Trop Geogr Med* 39: 115–122.
- Marennikova SS, Shelukhina EM, Khodakevich LN, Ianova NN, 1986. Isolation of the monkey pox virus from a wild African squirrel. *Vopr Virusol* 31: 238–241.
- Khodakevich L, Szczeniowski M, Manbu mD, Jezeck Z, Marennikova S, Nakano J, 1987. Monkeypox virus in relation to the ecological features surrounding human settlements in Bumba zone, Zaire. *Trop Geogr Med* 39: 56–63.
- Centers for Disease Control and Prevention, 2003. Update: multistate outbreak of monkeypox – Illinois, Indiana, Kansas, Missouri, Ohio, and Wisconsin, 2003. *MMWR Morb Mortal Wkly Rep* 52: 642–646.
- Anderson MG, Frenkel LD, Homann S, Guffey J, 2003. A case of severe monkeypox virus disease in an American child: emerging infections and changing professional values. *Pediatr Infect Dis J* 22: 1093–1096.
- Reed KD, Melski JW, Graham MB, Regnery RL, Sotir MJ, Wegner MV, Kazmierczak JJ, Stratman EJ, Li Y, Fairley JA, Swain GR, Olson VA, Sargent EK, Kehl SC, Frace MA, Kline R, Foldy SL, Davis JP, Damon IK, 2004. The detection of monkeypox in humans in the western hemisphere. *N Engl J Med* 350: 342–350.
- Sejvar JJ, Chowdary Y, Schomogyi M, Stevens J, Patel J, Karem K, Fischer M, Kuehnert MJ, Zaki SR, Paddock CD, Guarner J, Shieh WJ, Patton JL, Bernard N, Li Y, Olson VA, Kline RL, Loparev VN, Schmid DS, Beard B, Regnery RR, Damon IK, 2004. Human monkeypox infection: a family cluster in the mid-western United States. *J Infect Dis* 190: 1833–1840.
- Dhar AD, Werchniak AE, Li Y, Brennick JB, Goldsmith CS, Kline R, Damon I, Klaus SN, 2004. Tanapox infection in a college student. *N Engl J Med* 350: 361–366.
- Meyer H, Damon IK, Esposito JJ, 2004. Orthopoxvirus diagnostics. *Methods Mol Biol* 269: 119–134.
- Breman JG, 2000. Monkeypox: an emerging infection for humans? Scheld WM, Craig WA, Hughes JM, eds. *Emerging Infections 4*. Washington DC: American Society for Microbiology Press, 45–67.
- Mukinda VK, Mweme G, Kilundu M, Heymann DL, Khan AS, Esposito JJ, 1997. Re-emergence of human monkeypox in Zaire in 1996. *Lancet* 349: 1449–1450.
- Jezeck Z, Grab B, Dixon H, 1987. Stochastic model for interhuman spread of monkeypox. *Am J Epidemiol* 126: 1082–1092.
- Fine PE, Jezeck Z, Grab B, Dixon H, 1988. The transmission potential of monkeypox virus in human populations. *Int J Epidemiol* 17: 643–650.
- Antia R, Regoes RR, Koella JC, Bergstrom CT, 2003. The role of evolution in the emergence of infectious diseases. *Nature* 426: 658–661.
- Earl PL, Americo JL, Wyatt LS, Eller LA, Whitbeck JC, Cohen GH, Eisenberg RJ, Hartmann CJ, Jackson DL, Kulesh DA, Martinez MJ, Miller DM, Mucker EM, Shamblin JD, Zwiers SH, Huggins JW, Jahrling PB, Moss B, 2004. Immunogenicity of a highly attenuated MVA smallpox vaccine and protection against monkeypox. *Nature* 428: 182–185.

**Case classification**

Suspect

- Meets one of the epidemiologic criteria **and**
- Fever or unexplained rash **and** two or more other signs or symptoms with onset of first sign or symptom < 21 days after last exposure meeting epidemiologic criteria

Probable

- Meets one of the epidemiologic criteria **and**
- Fever **and** vesicular-pustular rash with onset of first sign or symptoms <21 days after last exposure meeting epidemiologic criteria **or** if rash is present but the type is not described, demonstrates elevated levels of IgM antibodies reactive with orthopox virus between at least days 7–56 after rash onset†

Confirmed

Meets one of the laboratory criteria

**Clinical criteria**

*Rash*

(macular, papular, vesicular, or pustular; generalized or localized; discrete or confluent)

*Fever*

(subjective or measured temperature of  $\geq 99.3^{\circ}\text{F}$  [ $\geq 37.4^{\circ}\text{C}$ ])

*Other signs and symptoms*

- Chills and/or sweats
- Headache
- Backache
- Lymphadenopathy
- Sore throat/cough
- Coryza
- Malaise/listlessness
- Prostration/distress

**Epidemiologic criteria**

- Exposure‡ to an African endemic animal species, individuals of which have been identified with elevated levels of orthopoxvirus-reactive antibodies **or**
- Exposure§ to a probable or confirmed human case of monkeypox

**Laboratory criteria**

- Isolation of monkeypox virus in culture **or**
- Demonstration of monkeypox virus DNA by polymerase chain reaction testing of a clinical specimen **or**
- Demonstration of presence of orthopoxvirus in tissue using immunohistochemical testing methods, or electron microscopy, in the absence of exposure to another orthopoxvirus.

**Exclusion criteria**

A case may be excluded as a suspect or probable monkeypox case if

- An alternative diagnosis can fully explain the illness¶ **or**
- The case was reported on the basis of primary or secondary exposure to an animal or a human (see epidemiologic criteria) subsequently determined not to have monkeypox, provided other possible epidemiologic exposure criteria are not present **or**
- The case is determined to be negative for non-variola generic orthopoxvirus by polymerase chain reaction testing of a well-sampled rash lesion **or**
- The case is determined to have undetectable levels of IgM antibody during the period of 7–56 days after rash onset.#

\* Amended from U.S. case definition (<http://www.cdc.gov/ncidod/monkeypox/casedefinition.htm>).

† Levels of circulating IgM antibody reactive with orthopoxvirus antigen are determined by ELISA and reported as optical density (OD) values.

‡ Includes living in a household as a pet, or pest, or having been obtained for another purpose.

§ Includes skin-to-skin or face-to-face contact.

¶ Factors that might be considered in assigning alternate diagnoses include the strength of the epidemiologic exposure criteria for monkeypox, the specificity of the diagnostic test, and the compatibility of the clinical presentation and course of illness for the alternative diagnosis.

# The optimal timing of specimen collection for determination of IgM levels is between days 7 and 56 post-rash onset. However, elevated levels of IgM antibodies may be detectable prior to day 7, or after day 56, post-rash onset; therefore, a negative result during this phase should not be interpreted to indicate an absence of monkeypox infection.