

SYMPTOMS OF INTESTINAL SCHISTOSOMIASIS PRESENTING DURING TREATMENT OF LARGE B CELL LYMPHOMA

MARTIN MONTES, A. CLINTON WHITE, JR., AND DIMITRIOS P. KONTOYIANNIS

Department of Internal Medicine, Section of Infectious Diseases, Baylor College of Medicine, Houston, Texas; Department of Infectious Diseases, Infection Control and Employee Health, The University of Texas M.D. Anderson Cancer Center, Houston, Texas

Abstract. We report a case of chronic intestinal schistosomiasis presenting in a previously asymptomatic 34-year-old woman from Saudi Arabia with large B cell lymphoma. The patient presented with abdominal pain, constipation, recurrent rectal bleeding, and persistent mild eosinophilia during chemotherapy. Stools were repeatedly negative for parasite ova, but duodenal and colonic biopsies demonstrated *Schistosoma* eggs and eosinophilic granulomatous inflammation. Immunosuppressed patients with schistosomiasis may have diminished egg excretion. Diagnosis requires a high index of suspicion since stool test results may be negative and intestinal biopsies may be needed to make the diagnosis.

CASE PRESENTATION

A 34-year-old woman from Riyadh, Saudi Arabia was referred to M.D. Anderson Cancer Center for treatment of a newly diagnosed large B cell lymphoma of the neck and pharyngeal areas in October 2000. She had presented with fever, sweats, weight loss, and rapidly growing bilateral neck masses. A biopsy of the mass showed diffuse large B cell lymphoma. There was no evidence of lymphoma in the mediastinum, abdomen, or central nervous system during staging evaluation. Mild eosinophilia was noted at the time of the diagnosis of lymphoma (10%, absolute eosinophil count = 500 cells/mm³). She began treatment with cyclophosphamide, adriamycin, vincristine, and prednisone (CHOP) plus rituximab followed by field radiation therapy completed in June 2001.

Four months after initiation of chemotherapy she noted intermittent diffuse abdominal pain, bloating, constipation, and occasional rectal bleeding. An upper endoscopy was remarkable for gastritis and the stomach biopsy demonstrated infection with *Helicobacter pylori*. A colonoscopy showed a perianal tear, internal hemorrhoids, and a normal-appearing mucosa. One month after completion of chemotherapy, the eosinophil count remained elevated (13–24%, absolute eosinophil count = 559–996 cells/mm³). The patient reported no new symptoms, but continued to complain of diffuse mild abdominal pain. She completed her radiation therapy and was considered to be in complete remission. She returned home to Saudi Arabia in June 2001. When she presented for follow-up in February 2002, she noted abdominal pain, constipation, and rectal bleeding. Her peripheral blood cell count showed persistent eosinophilia (18%; absolute eosinophil count = 828 cells/mm³). No evidence of lymphoma was found on re-staging evaluation. An upper endoscopy and colonoscopy were performed and mucosal biopsies were taken. The duodenal biopsy showed degenerated parasitic eggs in the lamina propria consistent with a *Schistosoma* infection. Biopsies of the colon and recto-sigmoid areas also showed degenerated parasitic eggs in the sub-mucosa consistent with schistosomiasis, as shown in Figure 1. There was associated granulomatous inflammation and a prominent eosinophilic infiltrate. Liver enzyme levels were within normal limits and there was no evidence of liver abnormalities by abdominal computed tomography. Renal function was preserved and no microscopic hematuria was detected. Three stool samples were negative for ova and parasites. A serologic test result was positive for infection with *Schistosoma mansoni* by an

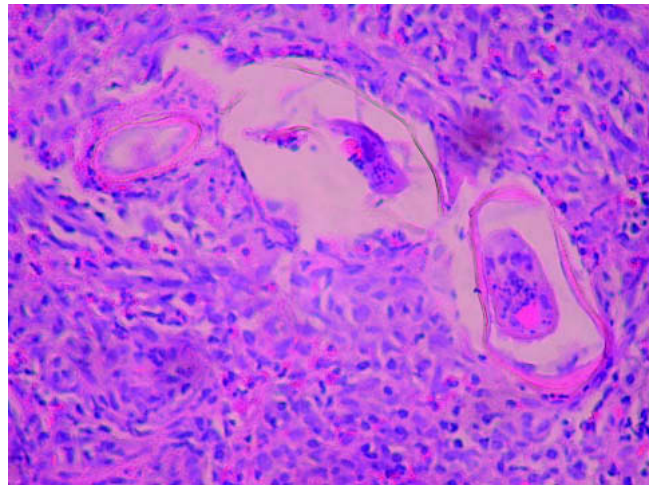


FIGURE 1. Colonic mucosa of the patient showing *Schistosoma* spp. eggs and granulomatous inflammation with an eosinophilic infiltrate (hematoxylin and eosin stained, magnification $\times 100$).

enzyme-linked immunosorbent assay (Focus Technologies, Cypress, CA). A diagnosis of chronic intestinal schistosomiasis was made. In view of these complex and chronic symptoms without alternative explanations, the patient was treated with praziquantel (dose = 40 mg/kg for one day divided in two doses) that she tolerated well. No relapse of her symptoms was appreciated after the 18-month follow up with few eosinophils in her blood (absolute eosinophil count = 315 cells/mm³) as per June 2003.

DISCUSSION

Schistosomiasis, a trematode parasitic infection, affects approximately 200 million individuals worldwide. Most infections are asymptomatic, although approximately 20 million people have severe disease manifestations.¹ Its geographic distribution is limited to the areas with the freshwater snails as intermediate hosts. *Schistosoma mansoni* and *S. haematobium* infections are endemic in Saudi Arabia.²

Intestinal schistosomiasis is the most common manifestation of infection with *S. mansoni* in endemic areas. The initial infection usually occurs during childhood. Adult worms then localize in the mesenteric vessels where they establish a chronic infection. Eggs produced by adult female parasites

are trapped in the intestinal wall, producing a T cell lymphocyte-mediated inflammatory reaction. Subsequent granuloma formation is thought to facilitate egg migration into the intestinal lumen and eggs are eliminated in the stools. When symptoms occur, intermittent bloody diarrhea, abdominal pain, and tenesmus are more frequently reported. Hyperemic areas of granular inflammation and polyps may be found at endoscopy. Hepatoesplenic schistosomiasis is the other major manifestation of chronic *S. mansoni* infection. Disease is associated with granulomatous and fibrotic reactions to the parasitic eggs in the liver.

Our patient had symptoms consistent with intestinal schistosomiasis. Interestingly, despite extensive involvement of the intestines shown in biopsies, all three stool test results were negative for *Schistosoma* eggs. This finding is consistent with published data in which egg output is reduced in immunosuppressed individuals. For example, a study of patients with acquired immunodeficiency syndrome and chronic schistosomiasis found a direct relationship between the number of eggs excreted in stools and the CD4+ T cell count levels of the infected individuals.³ Additionally, mice treated with dexamethasone and experimentally infected with *S. mansoni* were found to have decreased granuloma size formation in affected tissues.⁴ These findings support the evidence that the excretion of *S. mansoni* eggs is an immunologically mediated active process, and that in immunosuppressed patients the diagnosis of intestinal schistosomiasis may require not only stool testing but also serologic tests and/or tissue biopsies.

Our case is unique in that symptoms of intestinal schistosomiasis developed during lymphoma treatment. The coincidence of symptom manifestations during cancer treatment has not been noted previously. Whether symptoms were exaggerated by chemotherapy in our case cannot be determined. It is possible that immunosuppressive therapy allowed more eggs to be trapped in the intestinal tissue provoking occasional bleeding and abdominal pain.

Another important aspect of this case was the presence of eosinophilia. Eosinophilia is frequently associated with helminth infections, allergic diseases, and certain malignancies. Eosinophilia may be associated to Hodgkin's disease, non-Hodgkin's T cell type lymphomas, and to a lesser extent to B cell lymphomas.^{5,6} However, individuals migrating from developing countries, including cancer patients, are commonly affected by parasitic infections.^{7,8} In our case, mild eosinophilia was detected at the time of lymphoma diagnosis, but was not further evaluated. It was only after chronic remission was achieved that further investigation including endoscopy and intestinal biopsies along with serologic testing provided a definite diagnosis of schistosomiasis. The assay uses the microsomal fraction of adult *S. mansoni* worms (MAMA) as antigen and is thus highly specific (99%) and sensitive (96%) for detection of schistosomiasis caused by *S. mansoni*. Antibody levels do not correlate with intensity of infection.⁹

In summary, we report an unusual presentation of symptoms of chronic intestinal schistosomiasis in a lymphoma patient from Saudi Arabia presenting with bloody stools, abdominal pain, constipation, and mild eosinophilia. Eosinophilia in patients from areas endemic for parasitic infections should always be thoroughly investigated. In immunosuppressed patients, the diagnosis of schistosomiasis may not be achieved with routine stool examinations alone. Whether chemotherapy affects the clinical presentation of schistosomiasis deserves further investigation.

Received March 17, 2004. Accepted for publication May 28, 2004.

Authors' addresses: Martin Montes, Department of Internal Medicine, Infectious Diseases Section, Baylor College of Medicine, 1 Baylor Plaza, Room 535E, Houston TX, 77030, Telephone: 713-798-6846, Fax: 713-790-0681, E-mail: montes@bcm.tmc.edu. A. Clinton White Jr., Department of Internal Medicine, Infectious Diseases Section, Baylor College of Medicine, 1 Baylor Plaza, Room 535E, Houston, TX 77030, Telephone: 713-798-5246, Fax: 713-790-0681, E-mail: arthurw@bcm.tmc.edu. Dimitrios P. Kontoyiannis, Department of Infectious Diseases, Infection Control and Employee Health, The University of Texas M.D. Anderson Cancer Center, Box 0402, 1515 Holcombe Boulevard, Houston, TX 77030, Telephone: 713-792-0826, E-mail: dkontoyi@mdanderson.org.

REFERENCES

- White AC Jr, Fischer PR, 2003. Schistosomiasis. Feigen RD, Cherry JD, Demmler GJ, Kaplan SL, eds. *Textbook of Pediatric Infectious Diseases*. Fifth Edition. Philadelphia: W.B. Saunders, 2825–2834.
- Doumenge J, Mott K, Cheung C, Villenave D, Chapuis O, Perrin M, Reaud-Thomas G, 1987. *Atlas of the Global Distribution of Schistosomiasis*. Bordeaux: Presses Universitaires de Bordeaux, World Health Organization.
- Karanja DM, Colley DG, Nahlen BL, Ouma JH, Secor WE, 1997. Studies on schistosomiasis in western Kenya: I. Evidence for immune-facilitated excretion of schistosome eggs from patients with *Schistosoma mansoni* and human immunodeficiency virus coinfections. *Am J Trop Med Hyg* 56: 515–521.
- Pyrho Ados S, Ramos JA, Neto RM, Silva CS, Lenzi HL, Takiya CM, Gattass CR, 2002. Dexamethasone, a drug for attenuation of *Schistosoma mansoni* infection morbidity. *Antimicrob Agents Chemother* 46: 3490–3498.
- Watanabe K, Shinbo T, Kojima M, Naito M, Tanahashi N, Nara M, 1989. B-cell lymphoma associated with eosinophilia. *Cancer* 64: 1682–1685.
- Murata K, Yamada Y, Kamihira S, Atogami S, Tsukasaki K, Momita S, Amagasaki T, Sadamori N, Tomonaga M, Kinoshita K, Ichimaru M, 1992. Frequency of eosinophilia in adult T-cell leukemia/lymphoma. *Cancer* 69: 966–971.
- Menon BS, Abdullah MS, Mahamud F, Singh B, 1999. Intestinal parasites in Malaysian children with cancer. *J Trop Pediatr* 45: 241–242.
- Guarner J, Matilde-Nava T, Villasenor-Flores R, Sanchez-Mejorada G, 1997. Frequency of intestinal parasites in adult cancer patients in Mexico. *Arch Med Res* 28: 219–222.
- Hancock K, Tsang VC, 1986. Development and optimization of the FAST-ELISA for detecting antibodies to *Schistosoma mansoni*. *J Immunol Methods* 92: 167–176.